

**UNIVERSIDADE FEDERAL DE JUIZ DE FORA
FACULDADE DE ODONTOLOGIA
PROGRAMA DE PÓS GRADUAÇÃO EM CLÍNICA ODONTOLÓGICA**

CAIO BELLINI LOVISI

**ALTERAÇÕES TRIDIMENSIONAIS IMEDIATAS DA VIA AÉREA SUPERIOR
APÓS CIRURGIA ORTGNÁTICA COM ROTAÇÃO ANTI-HORÁRIA EM
PACIENTES RETROGNATAS**

JUIZ DE FORA

2018

CAIO BELLINI LOVISI

**ALTERAÇÕES TRIDIMENSIONAIS IMEDIATAS DA VIA AÉREA SUPERIOR
APÓS CIRURGIA ORTGNÁTICA COM ROTAÇÃO ANTI-HORÁRIA EM
PACIENTES RETROGNATAS**

Dissertação apresentada ao Programa de Pós-graduação em Clínica Odontológica, da Faculdade de Odontologia da Universidade Federal de Juiz de Fora, como requisito parcial para obtenção do título de Mestre. Área de concentração em Clínica Odontológica

Orientador: Prof. Dr. Bruno Salles Sotto-Maior

Co-orientador: Prof. Dra. Neuza Maria Souza Picorelli Assis

JUIZ DE FORA

2018

Ficha catalográfica elaborada através do programa de geração automática da Biblioteca Universitária da UFJF, com os dados fornecidos pelo(a) autor(a)

Lovisi, Caio Bellini.

Alterações tridimensionais imediatas da via aérea superior após cirurgia ortognática com rotação anti-horária em pacientes retrognatas / Caio Bellini Lovisi. -- 2018.

69 p.

Orientador: Bruno Sotto-Maior

Coorientadora: Neuza Assis

Dissertação (mestrado acadêmico) - Universidade Federal de Juiz de Fora, Faculdade de Odontologia. Programa de Pós Graduação em Clínica Odontológica, 2018.

1. Cirurgia Ortognática. 2. Via Aérea Superior. 3. Tomografia Computadorizada de Feixe Cônico. I. Sotto-Maior, Bruno , orient. II. Assis, Neuza, coorient. III. Título.

AGRADECIMENTOS

Agradeço primeiramente à Deus, por ter me dado forças que me permitiram a realização deste trabalho.

À UFJF por ter me acolhido desde o início da minha jornada profissional na odontologia, e novamente, agora como mestrando

À UERJ onde pude me sentir em casa e realizar meu grande sonho de ser cirurgião bucomaxilofacial, além de todo suporte para a realização deste trabalho

Ao meu orientador Bruno Salles Sotto-Maior, por ter me acreditado desde o início do projeto e sempre disponível quando solicitado

À minha co-orientadora, exemplo de profissional na área de cirurgia, Neuza Maria Souza Picorelli Assis, que tem todo meu respeito e admiração. Graças a sua enorme paciência e disponibilidade me permitiu o desenvolvimento deste trabalho

Ao meu preceptor professor Fábio Gambôa Ritto que me abriu as portas para residência de cirurgia e traumatologia bucomaxilofacial da UERJ. Companheiro de grandes cirurgias e ensinamentos, tem meu grande respeito e admiração, assim como todos os professores do Hospital Pedro Ernesto fundamentais na minha formação profissional.

À professora Karina Lopes Devito, pelo conhecimento e orientação em radiologia e estatística para a realização deste trabalho

A minha família, base de tudo sem o qual jamais teria chegado até aqui.

RESUMO

O presente estudo teve como objetivo a avaliação tridimensional da mudança imediata da orofaringe através da tomografia computadorizada de feixe cônico (TCFC) após cirurgia ortognática bimaxilar com rotação anti-horária, em diferentes avanços cirúrgicos. Os exames tomográficos foram realizados em 2 tempos distintos: T0 (pré-operatório) e T1 (pós-operatório com 15 dias). O total de 88 exames tomográficos de 44 paciente classe II (11 homens e 33 mulheres) foram selecionados e divididos em três grupos de acordo com avanço mandibular em milímetros (mm): G1 (< 5mm), G2 (entre 5 e 10 mm) e G3 (> 10mm). O programa Dolphin Imaging foi usado para mensurar a área sagital mediana (ASM), volume e área axial mínima (AAM) em cada grupo. Foi utilizado teste t de Student para amostras pareadas. O G1 não demonstrou diferença estatisticamente significativa, enquanto no G2 apenas a AAM demonstrou aumentos significativos ($p < 0,05$). Nos avanços superiores a 10 mm (G3) houve aumento significativo em todas as medidas avaliadas, sendo a AAM a mais sensível. O presente estudo demonstrou que ao menos 10 mm de avanço no ponto B em rotações anti-horárias são necessárias para o aumento de toda a orofaringe.

ABSTRACT

The purpose of this study was to quantify, through cone beam computed tomography (CBCT), the immediate three-dimensional changes in the oropharynx following bimaxillary orthognathic surgery (OS) with counterclockwise (CCW) rotation, in different surgical advancements. CBCT were taken at two distinct time intervals, preoperative (T0) and immediately postoperative, up to 15 days after surgery (T1). A total of 88 tomographic scans of 44 class II patients (11 men and 33 women) were selected and divided into three groups according to the following mandibular advancement in millimeters (mm): G1 (< 5 mm), G2 (between 5 and 10 mm) and G3 (> 10 mm). Dolphin Imaging® software was used to measure the medial sagittal area (MSA), volume, and minimum cross-sectional axial area (CSA) in each group. Statistical analysis was performed using a paired Student's t-test for the samples. No significant difference was observed in patients from G1, while G2 presented statistical improvements in CSA only ($p < 0.05$). Remarkable changes in all measures were observed when the advancements were superior to 10 mm (G3), with the CSA showing the most prominent change. The present study demonstrated that an at least 10 mm B point advancement in CCW was needed to improve the entire oropharynx.

SÚMARIO

1 Introdução.....	08
2 Poposição.....	10
3 Material e Método.....	11
4 Artigo.....	20
5 Considerações Finais.....	40
Referências Bibliográficas.	41
ANEXO A – Regras da revista da submissão do artigo (IJOMS)	45
ANEXO B – Parecer do comitê de ética da UFJF.....	61
ANEXO C – Parecer do comitê de ética da UERJ / HUPE.....	65

1 INTRODUÇÃO/JUSTIFICATIVA

O desenvolvimento correto e harmônico dos ossos da face está diretamente relacionado ao equilíbrio do sistema estomatognático, à presença de uma oclusão satisfatória, à estética facial e à morfologia das vias aéreas superiores. Quando este crescimento não ocorre de forma equilibrada, são encontradas as deformidades dentofaciais, como prognatismo ou retrognatismo maxilar e/ou mandibular, além das discrepâncias no sentido látero-lateral e vertical da face (TURNBULL e BATTAGEL, 2000).

Pacientes que possuem retrognatismo mandibular tendem a apresentar uma diminuição do espaço da via aérea superior (VAS) (RILEY *et al.*, 1983), representada pela nasofaringe, orofaringe e hipofaringe (RAMA *et al.*, 2002). Também são comumente encontrados em pacientes classe II, o comprimento vertical aumentado da VAS, o plano oclusal aberto e a retrusão do pogônio, que aumentam a resistência do fluxo de ar na região (ZINSER *et al.*, 2013). A diminuição do espaço aéreo e o aumento da resistência à passagem de ar podem levar ao severo estreitamento ou até mesmo à obstrução transitória da passagem de ar durante o sono nas áreas de maior constrição, causando a apneia obstrutiva do sono (LI, 2011; BIANCHI *et al.*, 2014).

A cirurgia ortognática é utilizada para correção das deformidades ósseas e discrepâncias de tecido mole da face (LOURO *et al.*, 2018). Os avanços bimaxilares podem causar grandes modificações esqueléticas e como consequência alteram a área e o volume da cavidade bucal e nasal (BIANCHI *et al.*, 2014), dependendo da região, da magnitude e direção do movimento (BRUNETTO *et al.*, 2014). Grandes mudanças e melhoras na VAS ocorrem em pacientes com avanços bimaxilares médios de 10 milímetros (mm) (FAIRBURN *et al.*, 2007; ABRAMSON *et al.*, 2011; BOYD *et al.*, 2013; BIANCHI *et al.*, 2014), entretanto o avanço na região mandibular demonstra ser mais efetivo (HERNÁNDEZ-ALFARO *et al.*, 2011). O avanço mandibular causa o estiramento da musculatura da faringe e supra hioidea que apresentam sua inserção nesta região (MEHRA *et al.*, 2001; LI, 2011). Este avanço pode ser potencializado com a rotação anti-horária do plano oclusal mandibular, quando o pogônio e o ponto B avançam mais do que o incisivo inferior (MEHRA *et al.*, 2001), maximizando o avanço do osso hioide, base de língua, e músculos genioglosso e geniohioide.

As mudanças nas VAS após a cirurgia ortognática podem ser avaliadas por exames de imagem em duas dimensões, com a utilização de radiografias cefalométricas (SAHOO *et al.*, 2012), porém apresentam limitações, pois avaliam de forma linear apenas as modificações no plano sagital, considerando uma alteração bidimensional de uma estrutura tridimensional (ABOUDARA *et al.*, 2009; CARVALHO *et al.*, 2012; KOCHAR *et al.*, 2016). A utilização de exames tridimensionais como tomografia computadorizada helicoidal para avaliação e reconstrução das vias aéreas pré e pós-operatórias também vem sendo utilizada em pacientes submetidos a cirurgias ortognática (FAIRNBURN *et al.*, 2007; ABRAMSON *et al.*, 2011; ZINSER *et al.*, 2013; BIANCHI *et al.*, 2014), porém há poucos relatos na literatura, com tomografia computadorizada de feixe cônico (TCFC) (HERNÁNDEZ–ALFARO *et al.*, 2011; CANELLAS *et al.*, 2016). Esta demonstra algumas vantagens sobre exames de TC helicoidal, com baixa dose de radiação, rápida aquisição e melhor custo-benefício (TSO *et al.*, 2009).

Na literatura, a alteração das vias aéreas superiores causadas pela cirurgia ortognática geralmente são relatadas em avanços bimaxilares lineares, com análises em exames de duas dimensões e apenas citando a média de avanço de toda uma amostra (SAHOO *et al.*, 2012; BIANCHI *et al.*, 2014). Porém há a necessidade de estratificar esses avanços e avaliá-los separadamente, analisando a repercussão na VAS, pois nem sempre esses grandes avanços são exequíveis devido à repercussão estética desfavorável, principalmente na região maxilar (ZINSER *et al.*, 2013). Portanto, a repercussão de diferentes avanços com rotação anti-horária na via aérea superior em 3D pode ser uma importante avaliação para os profissionais da cirurgia maxilofacial (SAHOO *et al.*, 2012).

2 PROPOSIÇÃO

O objetivo deste estudo foi avaliar tridimensionalmente as repercussões imediatas na VAS em diferentes avanços mandibulares após cirurgias bimaxilares com rotações anti-horárias em pacientes retrognatas.

3 MATERIAL E MÉTODO

Trata-se de um estudo observacional retrospectivo, onde foram analisados prontuários e exames de TCFC pré e pós-operatórias de cirurgia ortognática de pacientes retrognatas do Hospital Universitário Pedro Ernesto (HUPE) (Rio de Janeiro, RJ - Brasil), no período de janeiro de 2012 a janeiro de 2016. O estudo foi aprovado pelo comitê de ética e pesquisa da Universidade Federal de Juiz de Fora sob número de parecer 2.195.162 e pelo comitê de ética do HUPE sob número de parecer 2.450.559. Os critérios de inclusão adotados foram: exames de pacientes retrognatas (ângulo SNB < 78°), ambos gêneros, saudáveis (ASA I e ASA II), submetidos ao avanço do complexo bimaxilar com rotação anti-horária do plano oclusal. Foram excluídos pacientes submetidos a cirurgias ortognáticas prévias, com complicações trans-cirúrgicas, ou cirurgias prévias na região de cabeça e pescoço (MEHRA *et al.*, 2001; HONG *et al.*, 2011).

3.1 Exames de imagem

Foram avaliadas imagens pertencentes ao banco de imagens do HUPE, realizados no mesmo tomógrafo Kavo I-CAT (Imaging Sciences International, Hatfield, Pensilvânia, EUA), com “FOV” 22, rotação única de 360° para aquisição de imagens com cortes de 1 mm de espessura nos planos axial, sagital e coronal, com voxel de 0,3 mm, escala de 14 bits, tempo de varredura de 40 segundos, 120 kV e 5 mA e gravado em formato DICOM (Digital Imaging and Communication in Medicine). Os exames de TCFC foram realizados em dois intervalos de acordo com o protocolo do serviço de cirurgia maxilofacial da UERJ: pre-operatório (T0); pós-operatório imediato com 15 dias (T1). Não foi utilizado nenhum apoio para cabeça ou mento, com os pacientes sentados em posição natural de cabeça com o pescoço relaxado, sem causar hiperextensão ou hiperflexão (ARNETT *et al.*, 1999). Os pacientes foram manipulados manualmente em relação cêntrica, com os lábios relaxados e instruídos a não sorrir, não engolir e permanecerem parados. Todas as imagens foram posteriormente comparadas aos exames clínicos para determinar o correto posicionamento da cabeça e a realização do planejamento cirúrgico, levando em conta o trespasse horizontal e o posicionamento da cabeça por meio de fotos clínicas (Figura 1 e 2).

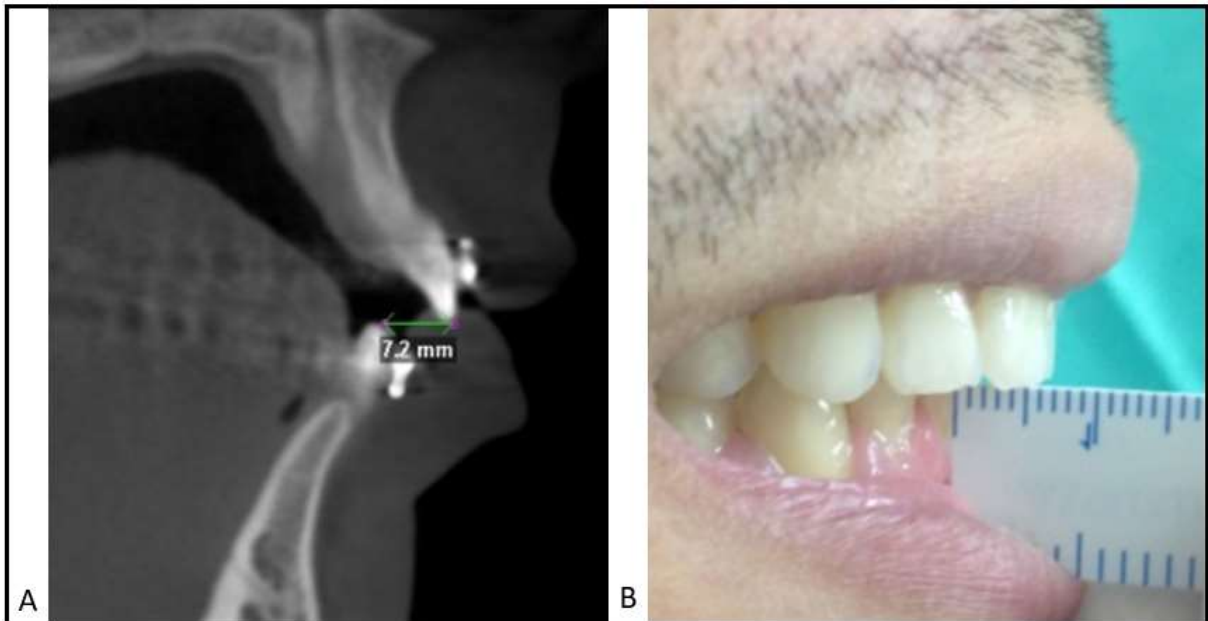


Figura 1 – (A) Reconstrução sagital ilustrativa da TCFC indicando o trespasse horizontal. (B) Foto clínica em vista lateral evidenciando o trespasse horizontal

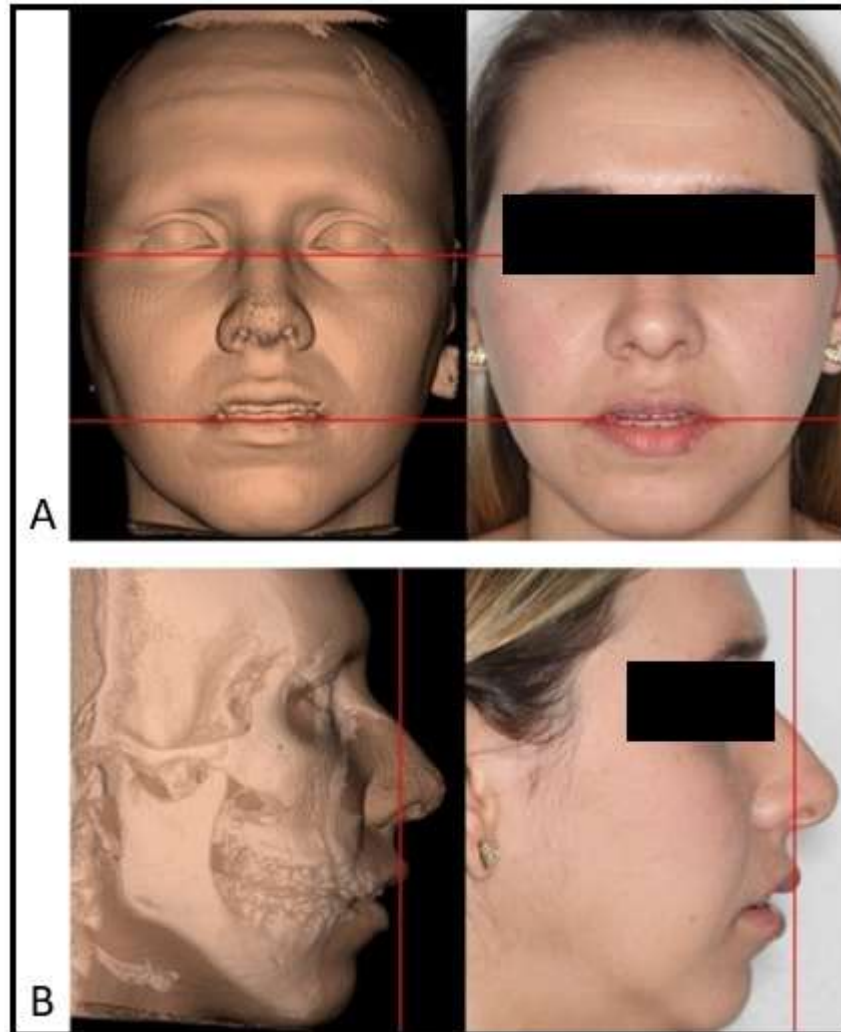


Figura 2 – Conferência do posicionamento da cabeça do paciente: (A) Reconstrução tridimensional da vista frontal seguindo como referência a foto clínica frontal; (B) Reconstrução tridimensional da vista lateral seguindo como referência a foto clínica de perfil

3.2 Procedimento cirúrgico

Foram realizadas cirurgias com avanços bimaxilares e rotação anti-horária do plano oclusal por meio de osteotomia Le Fort I e osteotomia sagital do ramo mandibular.

3.3 Sobreposição das imagens tomográficos

Os exames tomográficos T0 e T1 foram importados em formato DICOM para o Dolphin Imaging 11.7 (Dolphin Imaging and Management Solutions, Chatsworth, Calif., EUA). Em posição natural de cabeça, seguindo o protocolo do serviço da UERJ, foi utilizado a ferramenta “Superimpose Tool” na reconstrução sagital com 1 mm de espessura, e determinados os pontos fixos de referência como base de crânio, násion e sela túrcica em T0 e T1 que não sofreram alteração com a cirurgia para a sobreposição das imagens de forma automática no programa (Figura 3). A partir da sobreposição das imagens, utilizando a ferramenta “measure” foi mensurado de forma linear o avanço obtido em mm do ponto B em T0 e T1. De acordo com o avanço no ponto B, foram divididos em três grupos: G1 (avanço do ponto B < 5 mm), G2 (avanço do ponto B entre 5 e 10 mm) e G3 (avanço do ponto B > 10 mm). Utilizando a mesma ferramenta foram mensurados os avanços nos pontos: incisivo central inferior (ICI); incisivo central superior (ICS) e a espinha nasal anterior (ENA). Desta forma o avanço superior do ponto B em relação ao ICI e o maior avanço do ICS em relação a ENA caracterizou a rotação anti-horária do complexo em todos os casos (Figura 4).

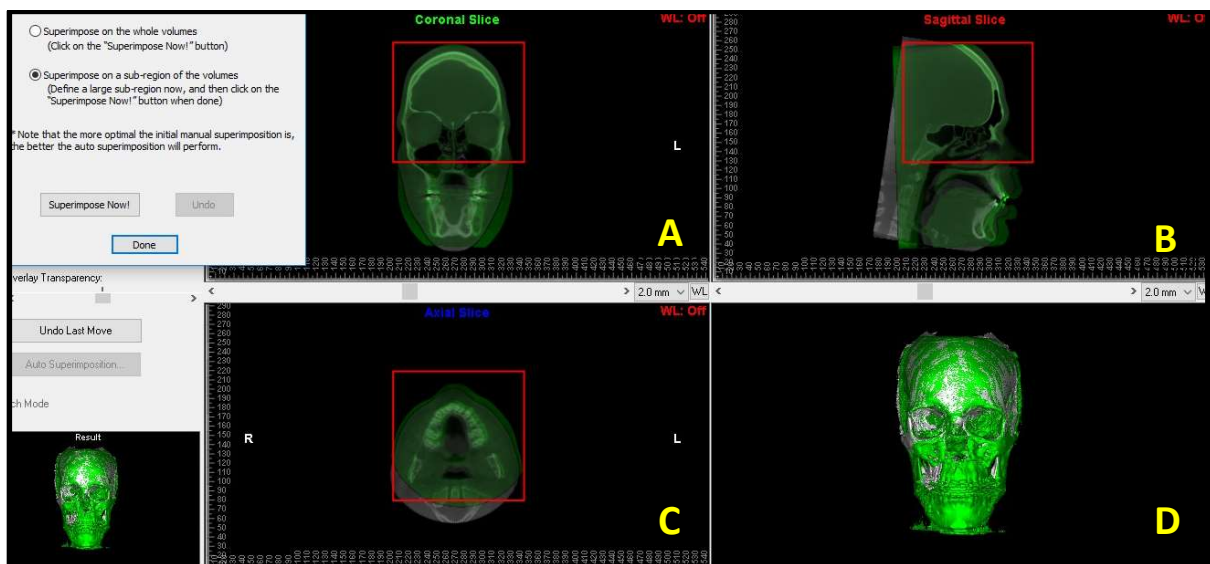


Figura 3 – Interface da ferramenta “superimpose” do programa Dolphin Imaging: (A), (B), (C): quadrado vermelho delimita a região com os pontos fixos que não sofreram movimentação cirúrgica, na vista coronal, sagital e axial respectivamente; (D) Reconstrução tridimensional das sobreposições de T0 e T1.

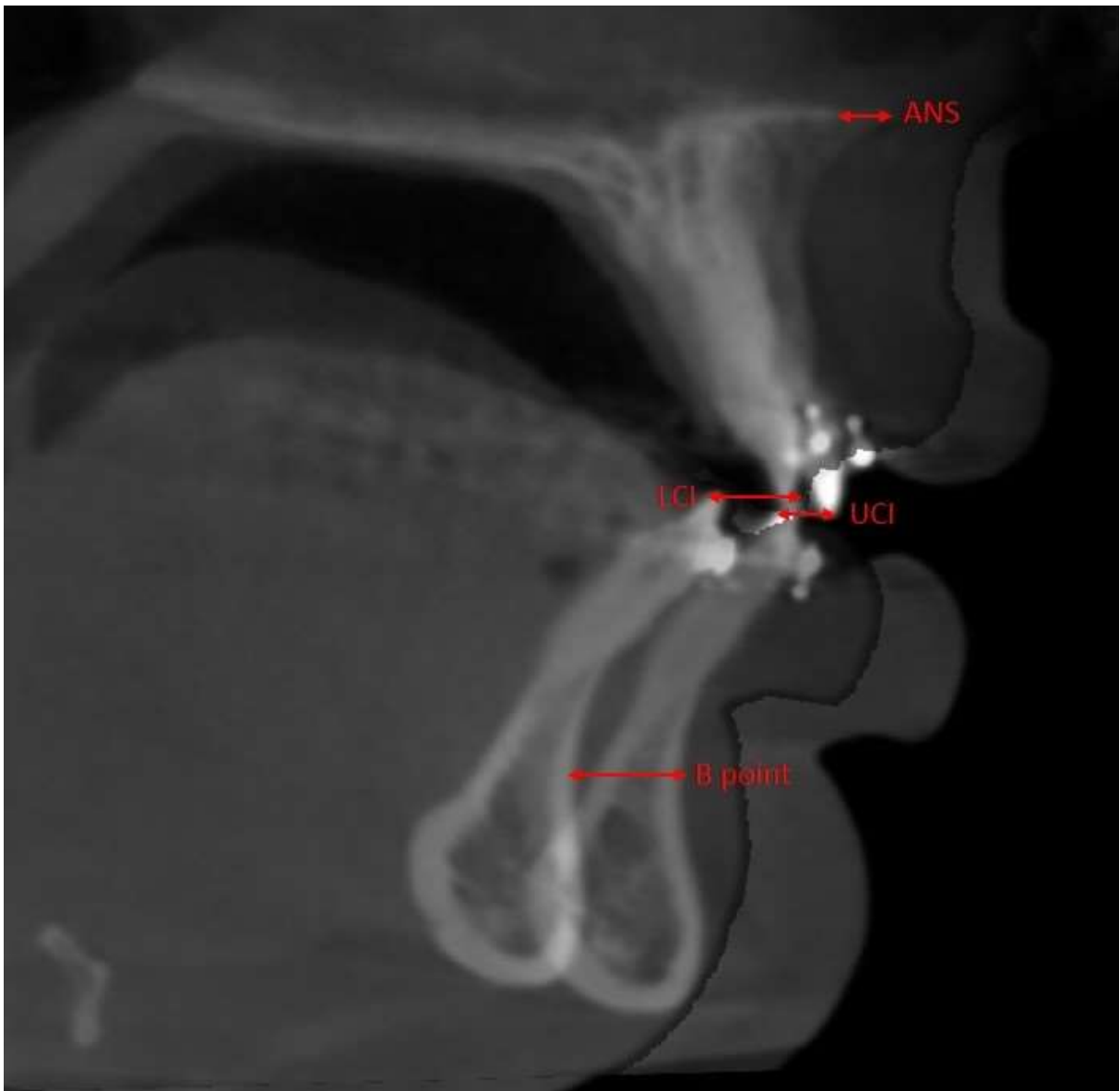


Figura 4 – Mensurações dos avanços nos pontos ENA, ICS, ICI e ponto B.

3.4 AVALIAÇÃO DA MUDANÇA DA VIA AÉREA SUPERIOR

O mesmo programa foi utilizado para reconstruir a VAS, com a ferramenta “Sinus/Airway Avaliation Tool”, (CARVALHO *et al.*, 2012; GONÇALVES *et al.*, 2013; RAFFAINI e PISANI, 2013; BRUNETTO *et al.*, 2014; MIRANDA *et al.*, 2015; CANELLAS *et al.*, 2016). A VAS foi delimitada na região da orofaringe a partir da reconstrução sagital mediana da mesma forma adota por Abramson *et al.*, (2011). Foram demarcados os pontos da espinha nasal posterior e da parede posterior da

faringe, formando uma linha paralela ao plano horizontal, delimitando o limite superior da via aérea a ser avaliada. O limite inferior foi demarcado na mesma reconstrução em dois pontos, um anterior na base da epiglote e outro na parede posterior da faringe, formando assim, uma linha paralela ao plano horizontal. Desta forma, a via aérea se estendeu do palato duro à base da epiglote no sentido vertical e no sentido ântero-posterior e látero-lateral pela própria faringe (paredes anterior, posterior e laterais) (ABRAMSON *et al.*, 2011) (Figura 5).

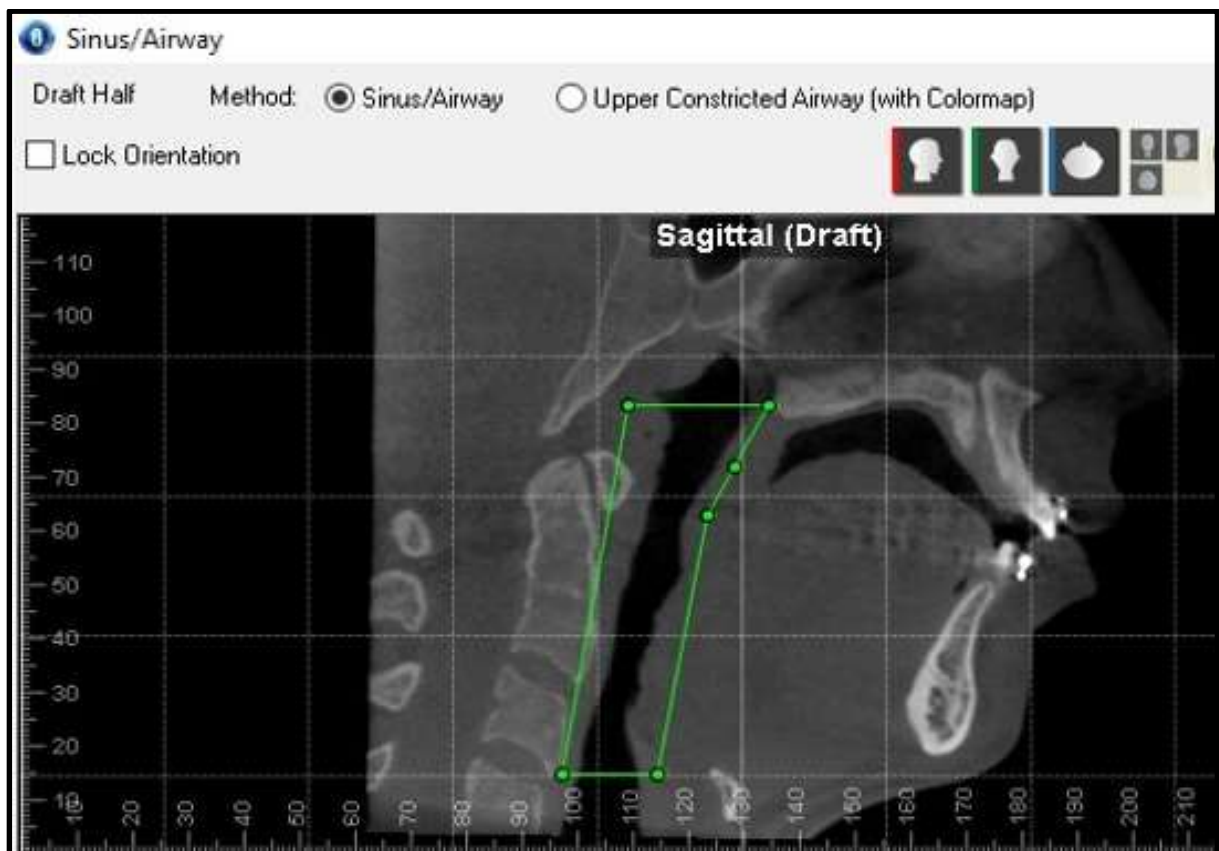

Figura 5 – Interface da ferramenta “sinus/airway” do programa Dolphin Imaging delimitando a região da orofaringe avaliada

Definidos os limites da via aérea a ser avaliada, foi utilizado a ferramenta “add seed points” no local da VAS, com a sensibilidade de via aérea padronizada em 25% (CARVALHO *et al.*, 2012). Seleccionada a região da orofaringe e a sensibilidade padronizada, foi utilizada a opção “update volume” para calcular a área sagital mediana (ASM) e o volume (Figura 6 e 7) e a opção “enable minimum axial area” para localizar e calcular a área axial mínima (AAM) (Figura 8).

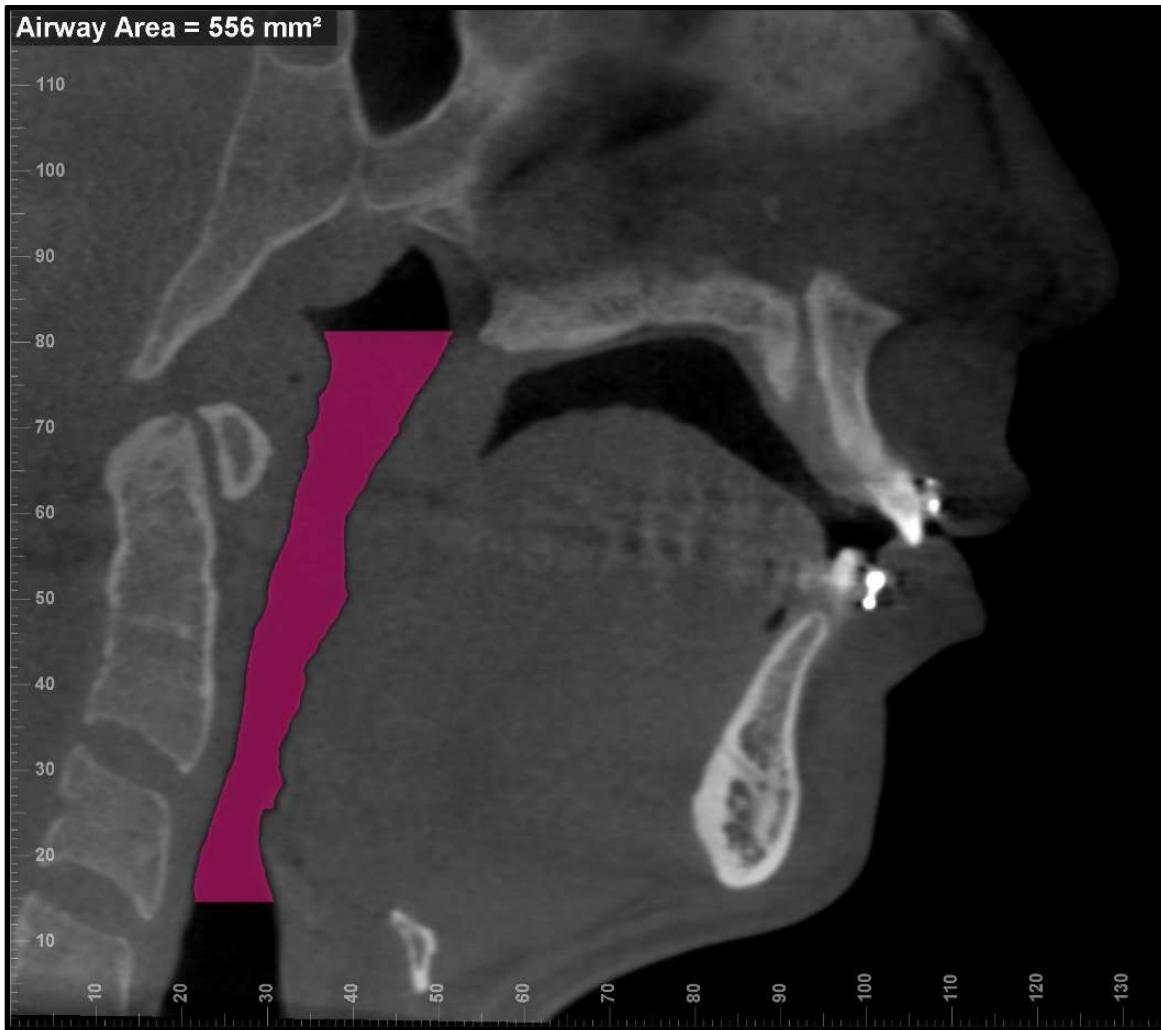


Figura 6 – Reconstrução sagital da TCFC evidenciando a área sagital mediana da orofaringe

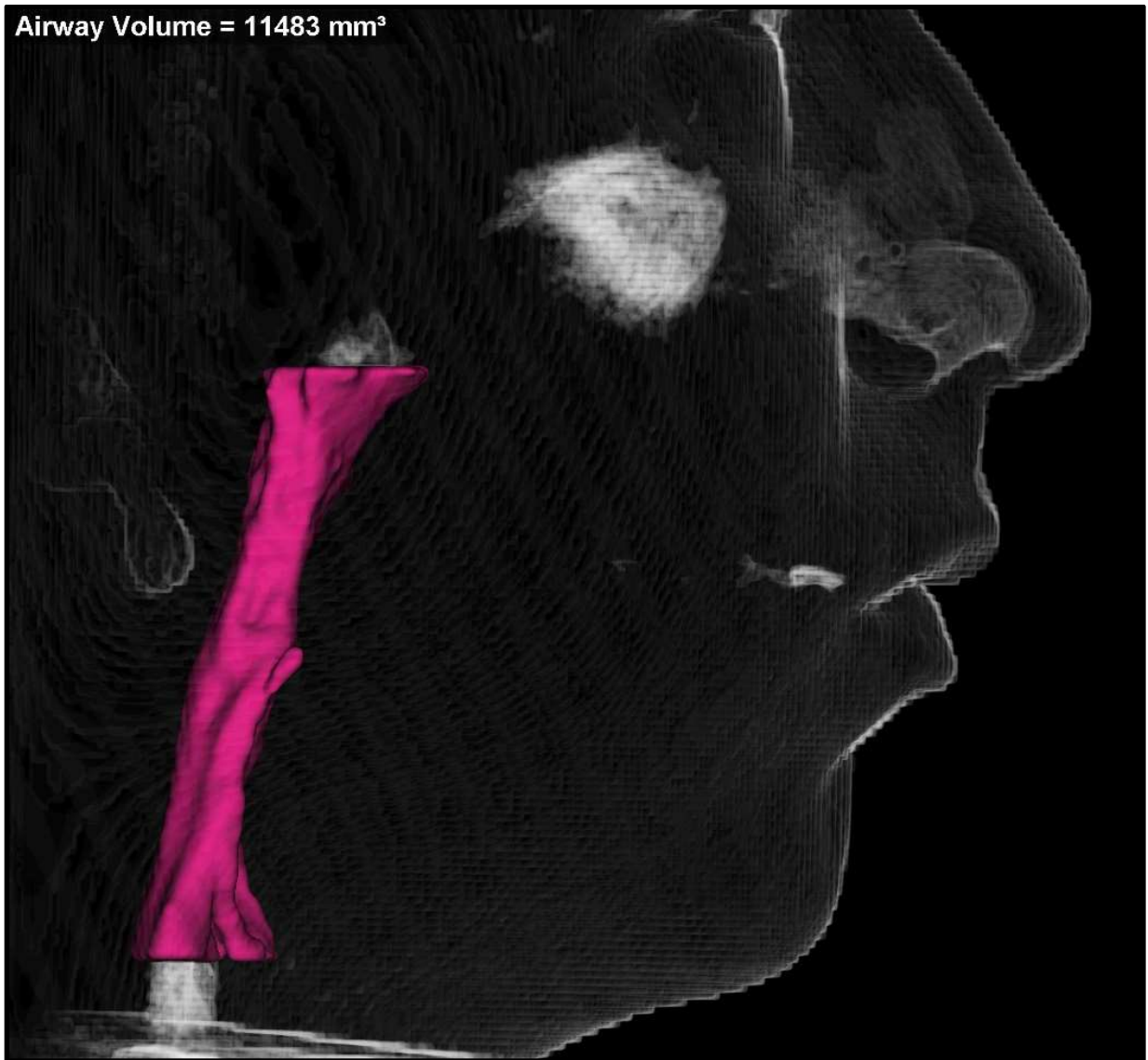

Figura 7 – Reconstrução tridimensional evidenciando o volume total da orofaringe

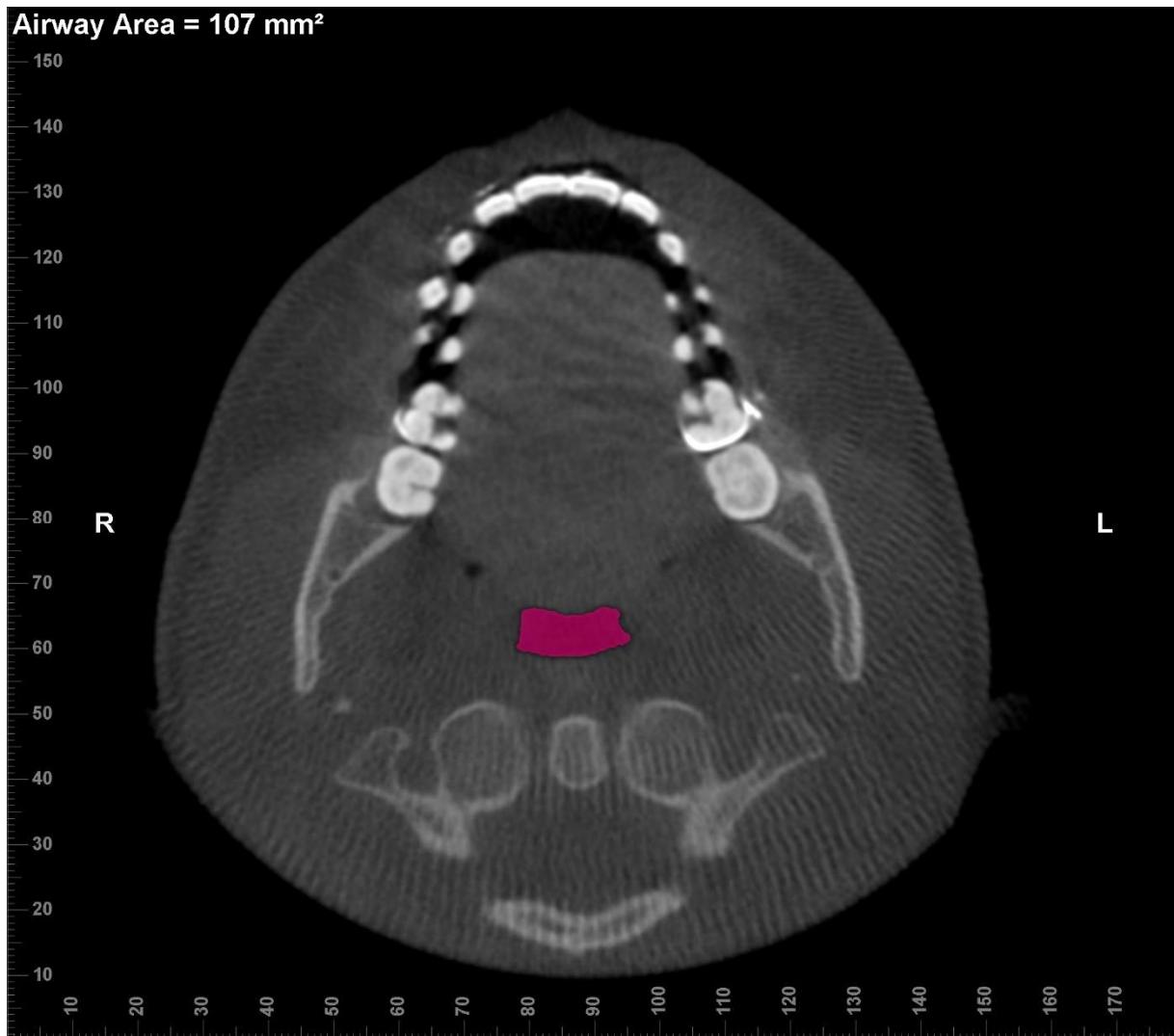


Figura 8 – Reconstrução axial da TCFC da área axial mínima da orofaringe na região de maior constrição

Todas as análises foram realizadas sob mesmas condições, pelo mesmo operador, limitando o número de imagens avaliadas por dia para evitar a fadiga visual (n = 5).

Para avaliar a reprodutibilidade de método, a amostra foi reavaliada após 1 mês, e foi aplicado o coeficiente de correlação de Pearson.

Para comparação das diferenças nos dois tempos (T0 e T1) das variáveis ASM, volume e AAM foi aplicado teste de normalidade da amostra e o teste T de Student pareado através do software IBM SPSS Statistics (versão 15,0; IBM Corp, Armonk, NY), com nível de significância de 95%.

4 ARTIGO

TITLE PAGE

Immediate three-dimensional changes in the oropharynx after different
counterclockwise rotation advancements

Authors:

Caio Bellini Lovisi, Neuza Maria Souza Picorelli Assis, Karina Lopes Devito, Fábio
Gamboa Ritto, Paulo Jose D'Albuquerque Medeiros, Bruno Salles Sotto-Maior

Department of Dental Clinic of Dental School of Federal University of Juiz de Fora

Adress: José Lourenço Kelmer Street, S/n - São Pedro, Juiz de Fora – Minas Gerais

ZipCode:36036-900

Bruno Salles Sotto-Maior

Giuseppe Verdi Street 910, São Lucas II Residence – Juiz de Fora, Minas Gerais,
Brazil

Zip Code: 36036-643 Phone: +55 32 984057663

E-mail: brunosottomaior@gmail.com

This work was supported by the Department of Oral and Maxillofacial Surgery,
Rio de Janeiro State University, Rio de Janeiro, Brazil

Key words: orthognathic surgery, three-dimensional image, airway remodeling

Running Heads: Impact of advances in the upper airway

ABSTRACT

The purpose of this retrospective study was to quantify, through cone beam computed tomography (CBCT), the immediate three-dimensional changes in the oropharynx following bimaxillary orthognathic surgery (OS) with counterclockwise (CCW) rotation, in different surgical advancements. CBCT were taken at two distinct time intervals, preoperative (T0) and immediately postoperative, up to 15 days after surgery (T1). A total of 88 tomographic scans of 44 class II patients (11 men and 33 women) were selected and divided into three groups according to the following mandibular advancement in millimeters (mm): G1 (< 5 mm), G2 (between 5 and 10 mm) and G3 (> 10 mm). Dolphin Imaging® software was used to measure the medial sagittal area (MSA), volume, and minimum cross-sectional axial area (CSA) in each group. Statistical analysis was performed using a paired Student's t-test. No significant difference was observed in patients from G1, while G2 presented statistical improvements in CSA only ($p \leq 0.05$). Remarkable changes in all measures were observed when the advancements were superior to 10 mm (G3), with the CSA showing the most prominent change. The present study demonstrated that an at least 10 mm B point advancement in counterclockwise was needed to improve the entire oropharynx.

INTRODUCTION

Patients presenting mandibular retrognathism tend to show a narrow upper airway (UA)¹. Other factors commonly found in class II patients, such as increased vertical length of the UA, high occlusal plane and retruded pogonion, may increase airflow resistance². The decreased airway space and the increased resistance to airflow may lead to a severe narrowing or to a transitory obstruction in the minimal axial area resulting in obstructive sleep apnea (OSA)^{3,4}.

Orthognathic surgery (OS) is performed to correct both bone deformities and facial soft tissue discrepancies⁵. Bimaxillary advancements may cause major skeleton modifications by increasing both UA area and volume⁴. Major changes in the UA are usually reported in patients subjected to bimaxillary advancements equal to or greater than 10 mm^{4,6,7,8}. However, mandibular movements seem to be more important than maxillary advancement⁹. Since mandibular advancement stretches the pharynx and the suprahyoid muscles, airway gain may be enhanced with a counterclockwise (CCW) rotation of the mandibular occlusal plane¹⁰. This happens because the pogonion and B point move forward farther than the teeth, thus maximizing the advancement of the hyoid bone, base of the tongue, genioglossus, and geniohyoid muscles¹⁰.

Two-dimensional lateral cephalograms have traditionally been used to evaluate airway parameters¹¹. However, these exams present limitations because they provide a two-dimensional change evaluation of a three-dimensional structure^{12,13,14}. Three-dimensional exams, such as computed tomographic (CT), have been used to reconstruct and evaluate airway spaces after orthognathic surgery^{2,4,6,7}. Even though CBCT presents some advantages over CT, such as lower

radiation dose and better cost-benefit¹⁵, there are still few reports in the literature evaluating UA changes using CBCT^{9,16}.

The few studies that evaluated UA changes after CCW rotation, using CBCT, only showed a mean advancement of 10 mm or more^{17,18,19}. Therefore, it would be interesting to investigate the effects of specific amount of mandibular advancements over the UA space, by performing a stratification of advancement magnitude. In this way, the necessary movement to correct the airways can be better correlated with the amount of movement necessary to correct the facial esthetics. The purpose of this study was to evaluate the immediate effect on the oropharynx of different mandibular advancements through CCW rotations in retrognathic patients.

MATERIALS AND METHODS

A retrospective analysis of the medical records and pre- and postoperative CBCT scans of patients subjected to orthognathic surgery at the University Hospital in Rio de Janeiro State (HUPE), Brazil, from January 2012 to January 2016 was performed. The inclusion criteria were: retrognathic patients (angle SNB < 78°) submitted to ortho-surgical treatment by bimaxillary CCW rotation, with available pre- and post-CBCT scans. The exclusion criteria were: history of adjuvant surgery in the soft tissues of the head and neck region, any trans-surgical or postoperative complications, and incomplete records^{10,16}. According to the advancement of B point, patients were divided into three groups: G1 (advancement < 5 mm), G2 (advancement between 5 and 10 mm) and G3 (advancement > 10 mm).

A standardized CBCT protocol was used according to the protocol of HUPE's Maxillofacial Surgery Department¹⁶ at two distinct time points: preoperative (T0) and immediately postoperative (T1) up to 15 days after surgery. All exams were conducted in the same tomograph i-CAT (Imaging Sciences International, Hatfield, Pennsylvania, USA), with a FOV 22 x 13 cm, a rotation of 360° to capture images with 1 mm thick sections in the axial, sagittal and coronal planes, a voxel of 0.3 mm, a 14-bit scale, 120 kV, 5 mA, and data recording using DICOM (Digital Imaging and Communication in Medicine). Patients were instructed to sit upright with a natural head position²⁰ and asked to breathe slowly and not to swallow. The mandible was positioned in a centric relation without the use of any device and only with manual manipulation¹⁶.

All the images preoperative and postoperative were imported to Dolphin Imaging 11.7 (Dolphin Imaging and Management Solutions, Chatsworth, Calif., USA) and were overlapped automatically in the same software with the "Superimpose

Tool". References used to superimpose both volumes included the skull base, nasion and sella turcica since they do not suffer from any changes with surgery.

After the superimposition, the "Measure Tool" was used to determine the linear advancement obtained at B point for each group division (G1, G2 or G3). Using the same tool, the linear advancement of the anterior nasal spine (ANS), upper central incisor (UCI), and lower central incisor (LCI) were also measured. A CCW rotation was configured when B point advanced more than the LCI, as well as in cases where the UCI advanced more than the ANS (Figure 1).

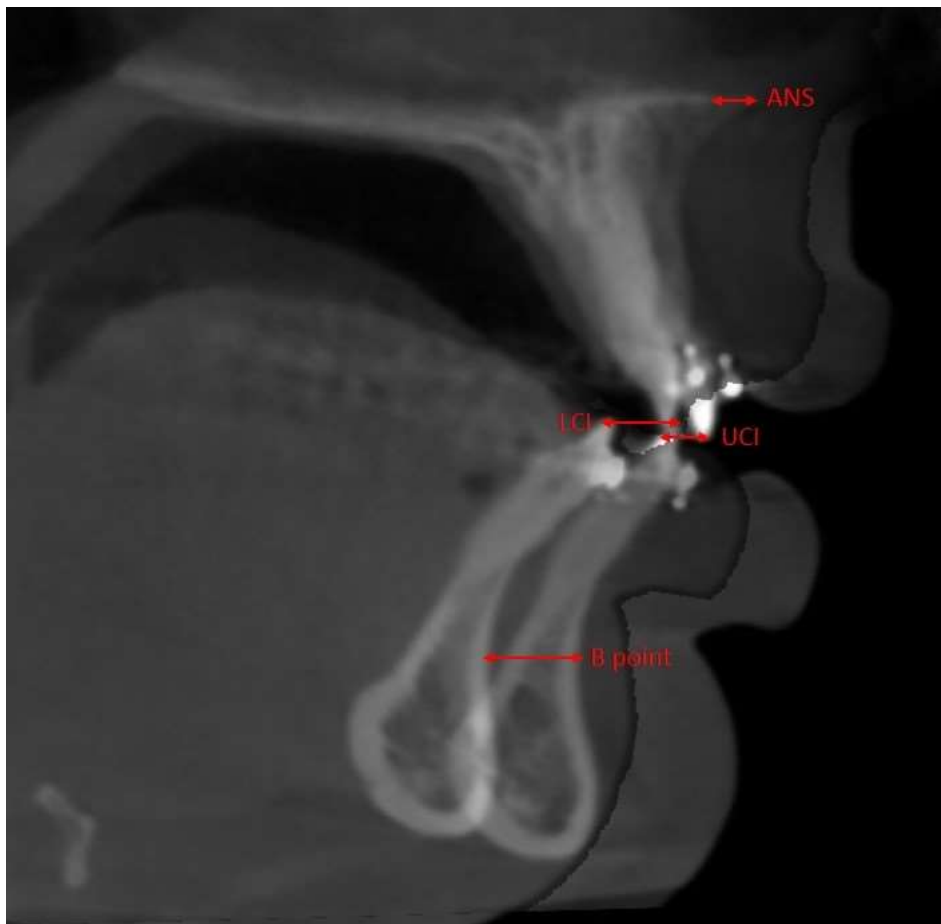


Figure 1. Superimposition of T0 and T1 and advancements at anterior nasal spine (ANS), upper central incisor (UCI), lower central incisor (LCI) and B point.

The "Sinus/Airway Evaluation Tool" in the Dolphin Imaging software was used for evaluation and reconstruction of the oropharynx^{13,16,17,18,19,21}. The superior and inferior limits of the oropharynx were determined in the medial sagittal reconstruction⁸ as a parallel line to the horizontal plane. The upper limit was defined at the level of the hard palate at the posterior nasal spine (PSA), and the inferior limit was set at the base of the epiglottis. Lateral and posterior limits were defined by the pharyngeal walls. Once these limits were defined, the "Add Seed Points Tool" was used to insert seed points inside this area. The detection sensitivity of the airway space was standardized at 25%, and the "Update Volume Tool" was used¹³ to measure the volume and the MSA of the delimited airway space (Figure 2). The minimal CSA was determined using the option "Enable Minimum Axial Area" in the axial view (Figure 3). All analyses were performed under the same conditions by the same operator, limiting the number of images assessed per day in order to avoid fatigue (n = 5). The whole sample was measured again after 1 month, and the Pearson correlation coefficient was applied to assess reproducibility.

Figure 2. Oropharynx delimited in the CBCT: (A) Sagittal reconstruction indicating the medial sagittal area (MSA); (B) Three-dimensional reconstruction indicating the volume of oropharynx.

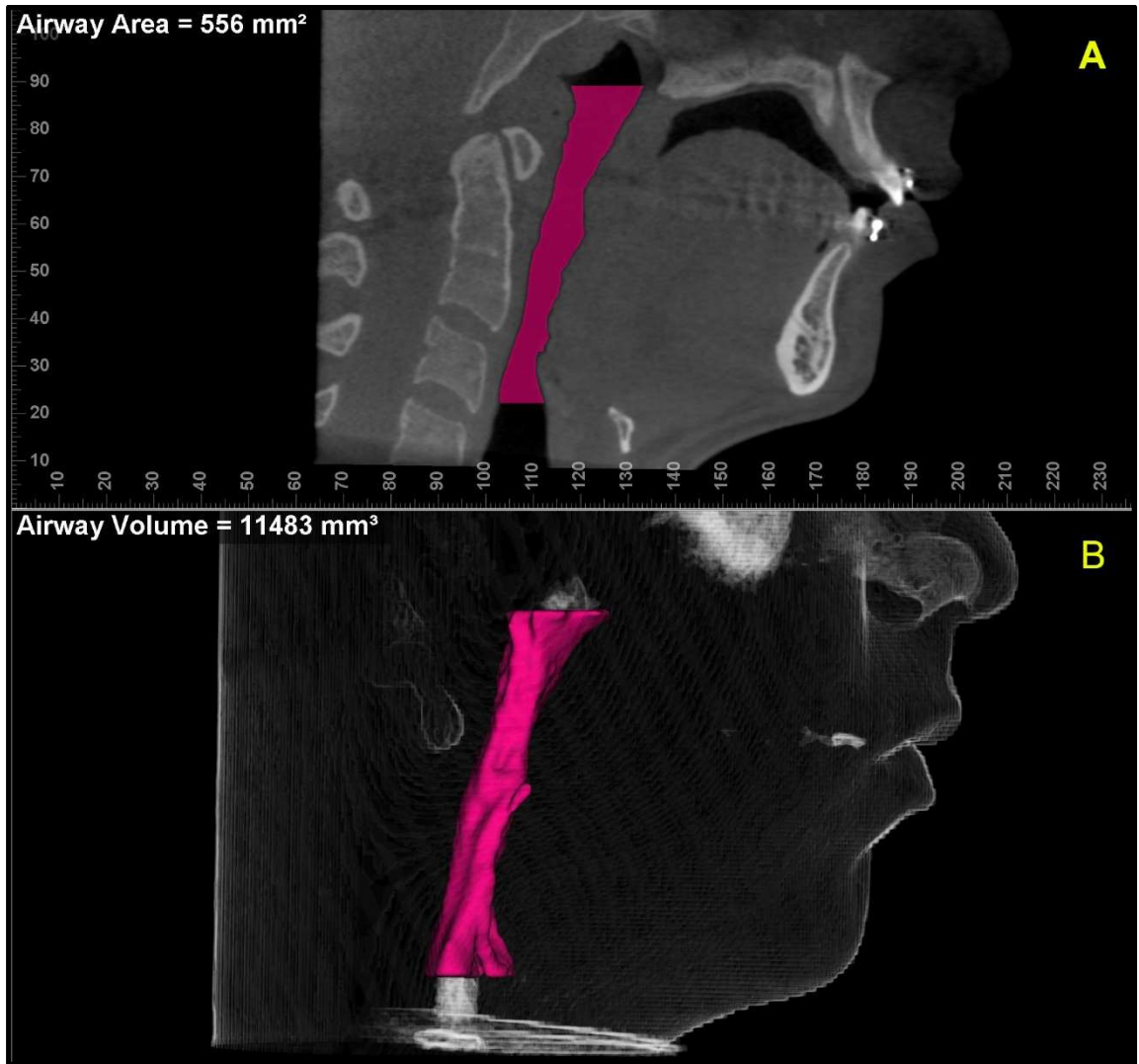


Figure 2. Oropharynx delimited in the CBCT: (A) Sagittal reconstruction indicating the medial sagittal area (MSA); (B) Three-dimensional reconstruction indicating the volume of oropharynx.

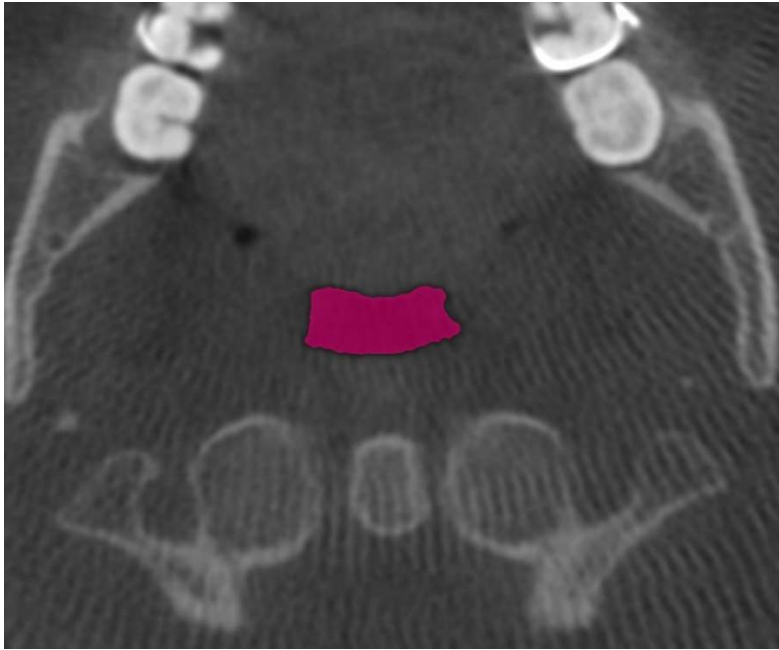


Figure 3. Axial reconstruction of CBCT indicating the minimum cross-sectional axial area (CSA)

Statistical analysis was performed using a paired Student's t-test to compare T0 and T1 MSA, volume and minimal CSA using SPSS (Statistics IBM software version 15.0; IBM Corp, Armonk, NY), with a significance level of 95%.

RESULTS

Of the total 138 pre- and postoperative images assessed, only 88 CBCT scans (44 patients) met the inclusion criteria for the study. In this sample, 33 patients were women and 11 were men, aged between 18 and 40 years. The Pearson correlation coefficient indicated an intra-examiner agreement of 0.93 in T0 and 0.96 in T1. Table 1 presents the mean, minimum and maximum values of the advances of the advancements at each point of the maxilla and mandible. Table 2 shows the comparison between T0 and T1 and the mean increase for the three variables studied (MSA, volume, and minimal CSA).

Table 1. Mean (mm), minimum (mm) and maximum (mm) values of the advances at different points

	G1 (n = 13)			G2 (n = 19)			G3 (n = 12)		
	Mean (SD)	Min	Max	Mean (SD)	Min	Max	Mean (SD)	Min	Max
UCI	1.85 (2.15)	0.0	5.4	3.10 (1.90)	0.0	6.8	4.00 (2.36)	2.5	7.9
ANS	0.08 (2.16)	- 3.5	3.2	1.46 (1.75)	-2.0	4.6	2.70 (2.11)	-1.6	5.1
LCI	2.11 (1.86)	0.0	4.3	5.41 (1.61)	2.8	8.5	7.67 (1.83)	5.1	10.3
Point B	3.34 (1.36)	1.5	4.8	8.05 (1.19)	6.2	9.9	12.55 (1.84)	10.4	16.5

UCI: upper central incisor; LCI: lower central incisor; ANS: anterior nasal spine

Table 2. Comparison of the means of T0 and T1 for the studied variables: MSA (mm²), Volume (mm³), and CSA (mm²)

	G1				G2				G3			
	T0	T1	Mean increase	P	T0	T1	Mean increase	P	T0	T1	Mean increase	P
	Mean (SD)	Mean (SD)			Mean (SD)	Mean (SD)			Mean (SD)	Mean (SD)		
MAS	797.15 (239.77)	835.46 (195.28)	38.31 (4.80%)	0.174	715.31 (233.99)	783.57 (204.04)	68.26 (9.54%)	0.072	553.66 (151.92)	705.91 (227.43)	152.25 (24.5%)	0.007*
Volume	19117.61 (8213.01)	18337.84 (6719.45)	-779.77 (4.08%)	0.295	15684.89 (6791.12)	17944.42 (8152.94)	2259.53 (14.40%)	0.099	12124.91 (4126.74)	16029.25 (6662.44)	3904.34 (32.20%)	0.003*
CSA	164.23 (89.03)	147.23 (74.84)	-17.00 (10.35%)	0.238	119.10 (61.35)	141.63 (74.14)	22.53 (18.92%)	0.050*	91,58 (61.69)	139.16 (84.06)	47.58 (51.95%)	0.012*

MAS: medial sagittal area; CSA: minimal cross-sectional area

*P≤0.05, statistically significant difference by paired T test.

DISCUSSION

Since mandibular movement seems to have a greater impact over the UA when compared to maxillary movements⁹, the present study used B point as the discriminating factor for group division. The oropharynx area was selected for assessment⁷ because it contains the greatest constriction region of the UA in retrognathic patients²². In addition, it is an area that seems to undergo major alterations due to mandibular movements following orthognathic surgery, particularly when compared to the nasopharynx and to the hypopharynx^{2,6,14}.

It is well established that CBCT is a simple and effective method to accurately analyze the airways¹², providing a more precise display of UA morphology and permitting measurements of MSA, minimal CSA, and volume². The major effect of CCW rotation observed in the current study was the improvement both volume and minimal CSA. These are the most important clinical modifications, because volume shows the total gain capacity of the UA, whereas minimal CSA is the most physiologically relevant plane since it is perpendicular to the airflow^{2,7,23}.

Advancements inferior to 5 mm (G1) did not produce significant changes in the oropharynx in any of the assessed variables. The lack of change may be related to the small amount of advancement, which may have been insufficient to stretch the musculature^{18,24}. Nevertheless, a significant increase in UA space with similar advancements has been reported. Ristow et al²⁵ found a significant difference in oropharynx volume and minimal CSA, with a mean value of mandibular advancement of 4.77 mm measured at three different points (left and right mental foramen and pogonion). The authors²⁵ used two different programs to evaluate mandibular advancement and the airways, instead of using Dolphin Imaging. According to El and

Palomo²⁶, the use of different software for assessing UA may generate differences among the results.

The literature presents significant improvements in minimal CSA and volume with mandibular advancements between 5 and 10 mm^{14,18,21}. This is in partial accordance with the present study since G2 presented significant improvements in minimal CSA, but no significant difference was observed when the oropharynx volume was evaluated. This difference in volume can be explained by the different limits of the oropharynx, surgical advancements, and the time elapsed for evaluation. Brunetto et al²¹ included part of the nasopharynx in the analysis and performed greater maxillary advancements (mean 4.71 mm). In the present study the mean maxillary advancement was 1.46 mm at ANS and 3.10 mm at UCI. Kochar et al¹⁴, in addition to using different limits than the present study, evaluated the oropharynx in isolated mandibular surgeries through CT. The difference between patients sitting for CBCT and the supine position in CT may alter the UA due to the gravitational forces that displace the tongue and soft palate posteriorly^{27,28}. Both studies^{14,21} evaluated the UA at least 5 months of postoperatively, which may be different from an evaluation conducted during the immediate postoperative period^{13,29}. Gonçalves et al¹³ reported significantly increased absolute values similar to those of the present study in terms of both volume (1896 mm³) and CSA (24 mm²) after a mean CCW rotation mandibular advancement of 9.65 mm and using the same software to evaluate these modifications. One possible explanation is the individual differences in muscle tone around the pharyngeal airways³⁰.

Advancements greater than 10 mm are routinely related to an enlargement of the airways with linear bimaxillary advancement^{4,6,7,8}. Nevertheless, these great maxillary advancements are not always possible from an esthetic point of view,

creating a biprotuse profile with a small naso-labial angle². Thus, the CCW rotation, in addition to improving the airway⁵, as shown in the present study (G3), enhances the esthetic profile of class II patients by optimizing the advancement of the pogonion⁵ and avoiding the unpleasant protrusion of the maxilla in the patient.

CCW rotation with mandibular advancements superior to 10 mm has been related to significant increases in MSA, volume and minimal CSA in the oropharynx^{2,13,17,19}. Raffaini and Pisani¹⁷ showed gains in the oropharynx of 34% in MSA, 56% in volume, and 112% in minimal CSA. Additionally, Miranda et al¹⁹ found gains of 178 mm² in surface area, 10.118 mm³ in volume, and 76.67 mm² in CSA; these values are greater than those in the present study. However, Raffaini and Pisani¹⁷ evaluated 10 patients with mandibular advancements ranging from 10 to 18 mm. Miranda et al¹⁹ evaluated 23 patients with a mean advancement of 14 mm and did not report the sensitivity of the airway used in Dolphin. In agreement with the present study, the authors^{2,17} found the minimal CSA to be most affected region in the oropharynx by CCW rotation.

Although the present study evaluated the immediate postoperative, the literature reports long-term stability of the skeletal movement after counterclockwise rotation with rigid fixation³¹. It has been reported that the surgical increased of the oropharyngeal airway space remained stable over the postsurgical follow-up of 34 months³². On the other hand, a long-term follow-up of the maintenance of the dimension of the UA after CCW rotation would require a strict control of all of the different variables that may predispose changes, such as an increase of the body mass index (BMI), muscle tone analysis, connective tissue flaccidity, and adipose tissue distribution¹⁶.

As a limitation of the present retrospective study some important clinical evaluation could not be done and controlled, such as BMI, the Berlin questionnaire, the Epworth Sleepiness Scale and polysomnography. A prospective study including different CCW advancements and evaluating three-dimensional changes with a strict control of the external factors that influences the changes in the UA should be conducted

The literature presents studies with significant increases in the oropharynx^{2,13,17,19}, although they used a single group sample with mean advancements equal or greater than of 10 mm. Since the UA changes after orthognathic surgery depend on the magnitude and direction of the movement⁷, the present study was able to demonstrate the effect that different ranges of advancement may have on the UA.

In conclusion, advancements of 5 – 10 mm at B point with a CCW rotation were able to increase MSA, volume, and minimal CSA; however, only the minimal CSA was significantly different. Mandibular advancements greater than 10 mm at B point were able to significantly improve the MSA, minimal CSA and the UA volume.

Funding: None

Competing Interests: None declared

Ethical approval:

This study was approved by the Juiz de Fora Federal University Committee (Number: 2.195.162)

This study was approved by the Pedro Ernesto University Hospital Committee (Number: 2.450.559)

Acknowledgements

This work was supported by the Department of Oral and Maxillofacial Surgery, Rio de Janeiro State University, Rio de Janeiro, Brazil

REFERENCES

1. Riley RW, Guilleminault C, Powell N, Herran J. Cephalometric analyses and flow volume loops in obstructive sleep apnea. *Sleep* 1983; 6: 303-311
2. Zinser MJ, Zachowb S, Sailer HF. Bimaxillary 'rotation advancement' procedures in patients with obstructive sleep apnea: a 3-dimensional airway analysis of morphological changes. *Int J Oral Maxillofac Surg* 2013; 42: 569–578. doi: 10.1016/j.ijom.2012.08.002
3. Li KK. Maxillomandibular advancement for obstructive sleep apnea. *J Oral Maxillofac Surg* 2011; 69: 687-694
4. Bianchi A, Betti E, Tarsitano A, Labate AMM, Lancellotti L, Marchetti C. Volumetric three-dimensional computed tomographic evaluation of the upper airway in patients with obstructive sleep apnoea syndrome treated by maxillomandibular advancement. *Br J Oral Maxillofac Surg* 2014; 52: 831-837. doi: 10.1016/j.bjoms.2014.07.101
5. Louro RS, Calasans-maia JA, Mattos CT, Masterson D, Calasans-maia MD, Maia LC. Three-dimensional changes to the upper airway after maxillomandibular advancement with counterclockwise rotation: a systematic review and meta-analysis. *Int J Oral Maxillofac Surg* 2018; 47 :622-629. doi: 10.1016/j.ijom.2017.11.003
6. Fairburn SC, Waite PD, Vilos G, Harding SM, Bernreuter W, Cure J, Cherala S. Three-dimensional changes in upper airways of patients with obstructive sleep apnea following maxillomandibular advancement. *J Oral Maxillofac Surg* 2007; 65 :6-12. doi: 10.1016/j.joms.2005.11.119
7. Abramson Z, Susarla MS, Lawler M, Bouchard C, Troulis M, Kaban LB. Three-dimensional computed tomographic airway analysis of patients with

- obstructive sleep apnea treated by maxillomandibular advancement. *J Oral Maxillofac Surg* 2011; 69 :677-686. doi: 10.1016/j.joms.2010.11.037
8. Boyd SB, Walters AS, Song Y, Wang L. Comparative effectiveness of maxillomandibular advancement and uvulopalatopharyngoplasty for the treatment of moderate to severe obstructive sleep apnea. *J Oral Maxillofac Surg* 2013; 71: 743-751. doi: 10.1016/j.joms.2012.10.003
 9. Hernández-alfaro F, Martínez RG, Bueno JM. Effect of mono and bimaxillary advancement on pharyngeal airway volume: cone-beam computed tomography evaluation. *J Oral Maxillofac Surg* 2011; 69: 395-400. doi: 10.1016/j.joms.2011.02.138
 10. Mehra P, Downie M, Pita MC, Wolford LM. Pharyngeal airway space changes after counterclockwise rotation of the maxillomandibular complex. *Am J Orthod Dentofacial Orthop* 2001; 120: 154-159. doi: 10.1067/mod.2001.114647
 11. Sahoo NK, Jayan B, Ramakirshna N, Chopra SS, Kochar G. Evaluation of upper airway dimensional changes and hyoid position following mandibular advancement in patients with skeletal class II malocclusion. *J Craniomaxillofac Surg* 2012; 23: 623-627. doi: 10.1097/SCS.0b013e318270fafd
 12. Aboudara C, Nielsen I, Huang JC, Maki K, Miller AJ, Hatcher D. Comparison of airway space with conventional lateral headfilms and 3-dimensional reconstruction from cone-beam computed tomography. *Am J Orthod Dentofacial Orthop* 2009; 135: 468-479. doi: 10.1016/j.ajodo.2007.04.043
 13. Carvalho ACG, Filho OM, Garciajunior IR, Araujo PM, Nogueira RLM. Cephalometric and three-dimensional assessment of superior posterior airway space after maxillomandibular advancement. *Int J Oral Maxillofac Surg* 2012; 41: 1102-1111. doi: 10.1016/j.ijom.2012.05.009

14. Kochar GD, Chakranarayan A, Kohli S, Kohli VS, Khanna V, Jayan B, Chopra SS, Verma M. Effect of surgical mandibular advancement on pharyngeal airway dimensions: a three-dimensional computed tomography study. *Int J Oral Maxillofac Surg* 2016; 45: 553–559. doi: 10.1016/j.ijom.2015.10.006
15. Tso HH, Lee JS, Huang JC, Maki K, Hatcher D, Miller AJ. Evaluation of the human airway using cone-beam computerized tomography. *Oral Surg Oral Med Oral Pathol Oral Radiol Endod* 2009; 108: 768-776. doi: 10.1016/j.tripleo.2009.05.026
16. Canellas JV, Barros HLM, Medeiros PJD, Ritto FG. Effects of surgical correction of class III malocclusion on the pharyngeal airway and its influence on sleep apnea. *Int J Oral Maxillofac Surg* 2016; 45: 1508-1512. doi: 10.1016/j.ijom.2016.09.002
17. Raffaini M, Pisani C. Clinical and cone-beam computed tomography evaluation of the three-dimensional increase in pharyngeal airway space following maxillo-mandibular rotation-advancement for Class II-correction in patients without sleep apnoea (OSA). *J Craniomaxillofac Surg* 2012; 41: 552-557. doi: 10.1016/j.jcms.2012.11.022
18. Gonçalves JR, Gomes LCR, Vianna AP, Rodrigues DB, Gonçalves DAG, Wolford LM. Airway space changes after maxillomandibular counterclockwise rotation and mandibular advancement with TMJ Concepts¹ total joint prostheses: three-dimensional assessment. *Int J Oral Maxillofac Surg* 2013; 42: 1014-1022. doi: 10.1016/j.ijom.2013.04.009
19. Miranda WS, Rocha VAC, Marques KLS, Neto AIT, Prado CJ, Zanetta-barbosa D. Three-dimensional evaluation of superior airway space after orthognathic surgery with counterclockwise rotation and advancement of the

- maxillomandibular complex in Class II patients. *Oral Surg Oral Med Oral Pathol Oral Radiol* 2015; 120: 453-458. doi: 10.1016/j.oooo.2015.06.037
20. Arnett GW, Jelic JS, Kim J, Cummings DR, Beress A, Worley M, Chung B, Bergman R. Soft tissue cephalometric analysis: diagnosis and treatment planning of dentofacial deformity. *Am J Orthod Dentofacial Orthop* 1999; 116: 239-253
21. Brunetto DP, Velasco L, Koerich L, Araújo, MTS. Prediction of 3-dimensional pharyngeal airway changes after orthognathic surgery: A preliminary study. *Am J Orthod Dentofacial Orthop* 2014; 146: 299-309. doi: 10.1016/j.ajodo.2014.05.024
22. Rama AN, Tekwani SH, Kushida CA. Sites of obstruction in obstructive sleep apnea. *Chest* 2002; 122: 1139-1147
23. Schendel SA, Broujerdi JA, Jacobsonc RL. Three-dimensional upper-airway changes with maxillomandibular advancement for obstructive sleep apnea treatment. *Am J Orthod Dentofacial Orthop* 2014; 146: 385-393. doi: 10.1016/j.ajodo.2014.01.026.
24. Li KK, Powell NB, Riley RW, Troell RJ, Guilleminault C. Long-term results of maxillomandibular advancement surgery. *Sleep Breath*: 2000; 4: 137-140. doi: 10.1007/s11325-000-0137-3
25. Ristow O, Rückschloß T, Berger M, Grotz T, Kargus S, Krisam J, Seeberger R, Engel M, Hoffmann J, Freudlsperger C. Short- and long-term changes of the pharyngeal airway after surgical mandibular advancement in class II patientsda three-dimensional retrospective study. *J Craniomaxillofac Surg* 2018; 46: 56-62. doi: 10.1016/j.jcms.2017.10.022

26. El H, Palomo JM. Measuring the airway in 3 dimensions: A reliability and accuracy study. *Am J Orthod Dentofacial Orthop*: 2010; 137: S50-S52. doi: 10.1016/j.ajodo.2010.01.014.
27. Fleisher KE, Krieger AC. Current trends in the treatment of obstructive sleep apnea. *J Oral Maxillofac Surg* 2007; 65: 2056-2068. doi: 10.1016/j.joms.2006.11.058
28. Kim MA, Kim BR, Young JK, Kim YJR, Park YH. Head posture and pharyngeal airway volume changes after bimaxillary surgery for mandibular prognathism. *J Craniomaxillofac Surg* 2014; 42: 531-535. doi: 10.1016/j.jcms.2013.07.022
29. Eggensperger N, Smolka K, Johner A, Rahal A, Thuer U, Iizuka T. Long-term changes of hyoid bone and pharyngeal airway size following advancement of the mandible. *Oral Surg Oral Med Oral Pathol Oral Radiol Endod* 2005; 99: 404-10. doi: 10.1016/j.tripleo.2004.07.019
30. Kim JS, Kim JK, Hong SC, Cho JH. Pharyngeal airway changes after sagittal split ramus osteotomy of the mandible: a comparison between genders. *J Oral Maxillofac Surg* 2010; 68: 1802-1806. doi: 10.1016/j.joms.2009.11.010
31. Chemello PD, Wolford LM, Buschang PH. Occlusal plane alteration in orthognathic surgery-part II: Long-term stability of results. *Am J Orthod Dentofacial Orthop* 1996; 106: 434-40. doi.org/10.1016/S0889-5406(94)70066-4
32. Gonçalves JR, Buschang PH, Goncalves DG, Wolford LM. Postsurgical Stability of Oropharyngeal Airway Changes Following Counter-Clockwise Maxillo-Mandibular Advancement Surgery. *J Oral Maxillofac Surg* 2006; 64:755-62. doi.org/10.1016/j.joms.2005.11.046

5 CONSIDERAÇÕES FINAIS

O presente estudo demonstrou a repercussão de diferentes grupos de avanços na orofaringe. Os avanços entre 5 – 10 mm no ponto B associado a rotação anti-horária, foram capazes de aumentar ASM, volume e AAM, contudo, apenas a AAM foi estatisticamente significativa. Os avanços mandibulares superiores a 10 mm no ponto B foram capazes de aumentar a orofaringe em ASM, volume e AAM.

REFERÊNCIAS BIBLIOGRÁFICAS

ABOUDARA, C.; NIELSEN, I.; HUANG, J.C.; MAKI, K.; MILLER, A.J.; HATCHER, D. Comparison of airway space with conventional lateral headfilms and 3-dimensional reconstruction from cone-beam computed tomography **Am J Orthop Dentofacial Orthop.**, v.135, n.4, p. 468-479, abr. 2009

ABRAMSON, Z.; SUSARLA, M.S.; LAWLER, M.; BOUCHARD, C.; TROULIS, M.; KABAN, L.B. Three-Dimensional computed tomographic airway analysis of patients with obstructive sleep apnea treated by maxillomandibular advancement **J Oral Maxillofac Surg.** v. 69, n. 3, p. 677-686, mar. 2011

ARNETT, G.W.; JELIC, J.S.; KIM, J.; CUMMINGS, D.R.; BERESS, A.; WORLEY, M.; CHUNG, B.; BERGMAN, R. Soft tissue cephalometric analysis: diagnosis and treatment planning of dentofacial deformity. **Am J Orthop Dentofacial Orthop.**, v.116, n.3, p.239-253, set. 1999.

BIANCHI, A.; BETTI, E.; TARSITANO, A. LABATE, A.M.M.; LANCELLOTTI, L., MARCHETTI, C., Volumetric three-dimensional computed tomographic evaluation of the upper airway in patients with obstructive sleep apnoea syndrome treated by maxillomandibular advancement **Br J Oral Maxillofac Surg.** v. 52, n. 9, p. 831-837, nov. 2014

BOYD, S.B.; WALTERS, A.S.; SONG, Y.; WANG, L. Comparative Effectiveness of Maxillomandibular Advancement and Uvulopalatopharyngoplasty for the Treatment of Moderate to Severe Obstructive Sleep Apnea **J Oral Maxillofac Surg.** v.71, n.4, p.743-751, abr. 2013.

BRUNETTO, D.P.; VELASCO, L.; KOERICH, L.; ARAÚJO, M.T.S. Prediction of 3-dimensional pharyngeal airway changes after orthognathic surgery: A preliminary study. **Am J Orthop Dentofacial Orthop.**, v. 146, n.3, p. 299-309 set. 2014.

CANELLAS, J.V.; BARROS, H.L.M., MEDEIROS, P.J.D.; RITTO, F.G. Effects of surgical correction of class III malocclusion on the pharyngeal airway and its influence on sleep apnea **Int. J. Oral Maxillofac. Surg.** v. 45, n. 12, p. 1508-1512, dez. 2016

CARVALHO, A.C.G.S.; MAGRO FILHO, O.; GARCIA JUNIOR, I.R.; ARAÚJO, P.M.; NOGUEIRA, R.L.M. Cephalometric and threedimensional assessment of superior posterior airway space after maxillomandibular advancement **Int. J. Oral Maxillofac. Surg.** v.41, n.9, p. 1102-1111, set. 2012

Eggensperger, N. Smolka, K. Johner, A. Rahal, A. Thuer, U. Iizuka, T. Long-term changes of hyoid bone and pharyngeal airway size following advancement of the mandible **Oral Surg Oral Med Oral Pathol Oral Radiol Endod** 2005; 99: 404–10.

EI, H.; PALOMO, J.M Measuring the airway in 3 dimensions: A reliability and accuracy study **Am J Orthod Dentofacial Orthop.** v.137, n.4, p.50-59, 2010

FAIRBURN, S.C.; WAITE, P.D.; VILOS, G.; HARDING, S.M.; BERNREUTER, W.; CURE, J.; CHERALA, S. Three-Dimensional Changes in Upper Airways of Patients With Obstructive Sleep Apnea Following Maxillomandibular Advancement **J Oral Maxillofac Surg.** v. 65, n. 1, p. 6-12, jan. 2007

FLEISHER, K.E.; KRIEGER, A.C. Current Trends in the Treatment of Obstructive Sleep Apnea **J Oral Maxillofac Surg.** v. 65, n. 10, p. 2056-2068, out. 2007

GONÇALVES, J.R.; GOMES, L.C.R.; VIANNA, A.P.; RODRIGUES, D.B.; GONÇALVES, D.A.G.; WOLFORD, L.M Airway space changes after maxillomandibular counterclockwise rotation and mandibular advancement with TMJ Concepts¹ total joint prostheses: three-dimensional assessment **Int. J. Oral Maxillofac. Surg.** v. 42, n. 8, p. 1014-1022, ago. 2013.

HERNÁNDEZ-ALFARO, F.; MARTÍNEZ, R.G.; BUENO, J.M. Effect of Mono and Bimaxillary Advancement on Pharyngeal Airway Volume: Cone-Beam Computed Tomography Evaluation. **J Oral Maxillofac Surg.**, v.69, n.11, p.395-400, nov. 2011

HONG, J.S.; PARK, Y.H.; KIM, Y.J.; HONG, S.M.; OH, K.M.; Three-Dimensional Changes in Pharyngeal Airway in Skeletal Class III Patients Undergoing Orthognathic Surgery **J Oral Maxillofac Surg.** v.69, n. 11, p. 401-408, nov. 2011.

KIM, J.S.; KIM, J.K.; HONG, S.C.; CHO, J.H Pharyngeal airway changes after sagittal split ramus osteotomy of the mandible: a comparison between genders. **J Oral Maxillofac Surg** v.68, n.8, p.1802-1806, 2010

KIM, M.A.; KIM, B.R.; YOUNG, J.K.; KIM, Y.J.R.; PARK, Y.H Head posture and pharyngeal airway volume changes after bimaxillary surgery for mandibular prognathism. **J Craniomaxillofac Surg** v.42, n.5, p.531-535, jul 2014

KOCHAR, G.D.; CHAKRANARAYAN, A.; KOHLI, S.; KOHLI, V. S.; KHANNA, V.; JAYAN, B.; CHOPRA, S.S.; VERMA, M. Effect of surgical mandibular advancement on pharyngeal airway dimensions: a threedimensional computed tomography study **Int. J. Oral Maxillofac. Surg.** v.45, n.5, p.553–559, mai 2016

LOURO, R.S.; CALASANS-MAIA, J.A.; MATTOS, C.T.; MASTERSON, D.; CALASANS-MAIA, M.D.; MAIA, L.C Three-dimensional changes to the upper airway after maxillomandibular advancement with counterclockwise rotation: a systematic review and meta-analysis **Int. J. Oral Maxillofac. Surg.** v.47, n.5, p.622-629, mai 2018

LI, K.K.; POWELL, N.B.; RILEY, R.W.; TROELL, R.J.; GUILLEMINAULT, C Long-term results of maxillomandibular advancement surgery. **Sleep Breath** v.4, n.3, p.137-140, 2000

LI, K.K. Maxillomandibular Advancement for Obstructive Sleep Apnea **J Oral Maxillofac Surg.** v.69, n.3, p.687-694, mar. 2011

MEHRA, P.; DOWNIE, M.; PITA, M.C.; WOLFORD, L.M. Pharyngeal airway space changes after counterclockwise rotation of the maxillomandibular complex **Am J Orthod Dentofacial Orthop.** v.120, n.2, p.154-159, ago. 2001

MIRANDA, W.S.; ROCHA, V.A.C.; MARQUES, K.L.S.; NETO, A.I.T.; PRADO, C.J.; BARBOSA, D.Z Three-dimensional evaluation of superior airway space after orthognathic surgery with counterclockwise rotation and advancement of the maxillomandibular complex in Class II patients **Oral Surg Oral Med Oral Pathol Oral Radiol** v.120, n.4, p.453-458, out. 2015

RAFFAINI, M.; PISANI, C Clinical and cone-beam computed tomography evaluation of the three-dimensional increase in pharyngeal airway space following maxillo-mandibular rotation-advancement for Class II-correction in patients without sleep apnoea (OSA) **The Journal of Craniofacial Surgery** v. 41, n. 7, p. 552-557, out. 2013

RAMA, A.N.; TEKWANI, S.H.; KUSHIDA, C.A.; Sites of Obstruction in Obstructive Sleep Apnea **Chest** v.122, n.4, p.1139-1147, out. 2002

RILEY R.W.; GUILLMINAULT, C.; POWELL, N.; HERRAN, J. Cephalometric analyses and flow volume loops in obstructive sleep apnea. **Sleep** v.6, n.4, p.303-311, abr. 1983.

RISTOW, O.; RÜCKSCHLOß, T.; BERGER, M.; GRÖTZ, T. KARGUS, S.; KRISAM, J.; SEEBERGER, R.; ENGEL, M.; HOFFMANN, J.; FREUDLSPERGER, C Short- and long-term changes of the pharyngeal airway after surgical mandibular advancement in Class II patientsda three-dimensional retrospective study **The Journal of Craniofacial Surgery** v. 46, n. 1, p. 56-62, jan. 2018

SAHOO, N.K.; JAYAN, B.; RAMAKIRSHNA, N.; CHOPRA, S.S.; KOCHAR, G. Evaluation of Upper Airway Dimensional Changes and Hyoid Position Following Mandibular Advancement in Patients With Skeletal Class II Malocclusion **The Journal of Craniofacial Surgery** v. 23, n. 6, p. 623-627, nov. 2012

SCHENDEL, S.A.; BROUJERDI, J.A.; JACOBSONC, R.L Three-dimensional upper-airway changes with maxillomandibular advancement for obstructive sleep apnea treatment **Am J Orthod Dentofacial Orthop** v. 146, n. 3, p. 385-393, set. 2014

TSO, H.H.; LEE, J.S.; HUANG, J.C.; MAKI, K.; HATCHER, D.; MILLER, A.J.; Evaluation of the human airway using cone-beam computerized tomography **Oral Surg Oral Med Oral Pathol Oral Radiol Endod.** v.108, n.5, p.768-776, nov. 2009

TURNBULL, N.; BATTAGEL, J. The effects of orthognathic surgery on pharyngeal airway dimensions and quality of sleep. **J Orthod.** v.27, n.3, p.235-247, set. 2000.

ZINSER, M.J.; ZACHOWB, S.; SAILER, H.F. Bimaxillary 'rotation advancement' procedures in patients with obstructive sleep apnea: a 3-dimensional airway analysis of morphological changes **Int. J. Oral Maxillofac. Surg.** v.42 n.11, p.569–578, nov. 2013.

ANEXO A - REGRAS DA REVISTA DA SUBMISSÃO DO ARTIGO

Guide for Authors

Would authors please note that the reference style for the journal has now changed. Please pay special attention to the guidelines under the heading "References" below

Authors wishing to submit their work to the journal are urged to read this detailed guide for authors and comply with all the requirements, particularly those relating to manuscript length and format. This will speed up the reviewing process and reduce the time taken to publish a paper following acceptance.

Online Submission

Submission and peer-review of all papers is now conducted entirely online, increasing efficiency for editors, authors, and reviewers, and enhancing publication speed. Authors requiring further information on online submission are strongly encouraged to view the system, including a tutorial, at <http://ees.elsevier.com/ijoms>. For additional enquiries please visit our Support Center. Once a paper has been submitted, all subsequent correspondence between the Editorial Office (ijoms@elsevier.com) and the corresponding author will be by e-mail.

Editorial Policy

A paper is accepted for publication on the understanding that it has not been submitted simultaneously to another journal, has been read and approved by all authors, and that the work has not been published before. The Editors reserve the right to make editorial and literary corrections. Any opinions expressed or policies advocated do not necessarily reflect the opinions and policies of the Editors.

Declarations

Upon submission you will be required to complete and upload the declarations page (pdf version or word version) to declare funding, conflict of interest and to indicate that ethical approval was given – all studies involving patients must have patient consent and ethical committee approval, please refer to the section on 'Ethics' below. This information must also be inserted into your manuscript under the acknowledgements section with the headings below. Upon submission you will be

required to complete and upload this form (pdf version or word version) to declare funding, conflict of interest, and to indicate whether ethical approval and patient consent were given and you must also upload with it the IRB approval or exemption letter. This applies to original research articles carried out on humans, including observational studies and case series. Ethical committee approval or exemption is not needed for systematic review articles or articles that are not based on humans or animals. Research on animal studies should be uploaded with the appropriate ethical approval for the study. If the ethical approval or exemption letter is not in English please provide the text in English. Lastly you must confirm that all authors have agreed to the submission.

PLEASE NOTE that all funding must be declared at first submission, as the addition of funding at acceptance stage may invalidate the acceptance of your manuscript.

Authorship

All authors should have made substantial contributions to all of the following: (1) the conception and design of the study, or acquisition of data, or analysis and interpretation of data

(2) drafting the article or revising it critically for important intellectual content

(3) final approval of the version to be submitted.

Normally one or two, and no more than three, authors should appear on a short communication, technical note or interesting case/lesson learnt. Full length articles may contain as many authors as appropriate. Minor contributors and non-contributory clinicians who have allowed their patients to be used in the paper should be acknowledged at the end of the text and before the references.

The corresponding author is responsible for ensuring that all authors are aware of their obligations.

Before a paper is accepted all the authors of the paper must sign the Confirmation of Authorship form. This form confirms that all the named authors agree to publication if the paper is accepted and that each has had significant input into the paper. Please

download the form and send it to the Editorial Office. (pdf version or word version) It is advisable that to prevent delay this form is submitted early in the editorial process.

Acknowledgements

All contributors who do not meet the criteria for authorship as defined above should be listed in an acknowledgements section. Examples of those who might be acknowledged include a person who provided purely technical help, writing assistance, or a department chair who provided only general support. Authors should disclose whether they had any writing assistance and identify the entity that paid for this assistance.

Conflict of interest

At the end of the main text, all authors must disclose any financial and personal relationships with other people or organisations that could inappropriately influence (bias) their work. Examples of potential conflicts of interest include employment, consultancies, stock ownership, honoraria, paid expert testimony, patent applications/registrations, and grants or other funding. If an author has no conflict of interest to declare, this should be stated.

Role of the funding source

All sources of funding should be declared as an acknowledgement at the end of the text. Authors should declare the role of study sponsors, if any, in the study design, in the collection, analysis and interpretation of data; in the writing of the manuscript; and in the decision to submit the manuscript for publication. If the study sponsors had no such involvement, the authors should so state.

Open access

This journal offers you the option of making your article freely available to all via the ScienceDirect platform. To prevent any conflict of interest, you can only make this choice after receiving notification that your article has been accepted for publication. The fee of \$3,000 excludes taxes and other potential author fees such as color charges. In some cases, institutions and funding bodies have entered into agreement with Elsevier to meet these fees on behalf of their authors. Details of these agreements are available at <http://www.elsevier.com/fundingbodies>. Authors of

accepted articles, who wish to take advantage of this option, should complete and submit the order form (available at <http://www.elsevier.com/locate/openaccessform.pdf>). Whatever access option you choose, you retain many rights as an author, including the right to post a revised personal version of your article on your own website. More information can be found here: <http://www.elsevier.com/authorsrights>.

Ethics

Any manuscript concerned with human subjects, medical records, or human tissue that is submitted to the International Journal of Oral and Maxillofacial Surgery should comply with the principles stated in the Declaration of Helsinki “Ethical Principles for Medical Research Involving ‘Human Subjects’”, adopted by the 18th World Medical Assembly, Helsinki, Finland, June 1964, and as amended most recently by the 64th World Medical Assembly, Fontaleza, Brazil, October 2013.

The manuscript should contain a statement that the work has been approved by the appropriate Ethical Committee related to the institution(s) in which the work was performed, and that subjects gave informed consent to the work. The International Journal of Oral and Maxillofacial Surgery requires institutional Ethics Committee approval for all human studies. For retrospective studies of records either a statement of approval or a statement of exemption from the Committee is appropriate. This statement should be provided upon submission of the manuscript.

Studies involving experiments with animals must state that their care was in accordance with institution guidelines.

Patient confidentiality

Patients have a right to privacy. Therefore identifying information, including patients' images, names, initials, or hospital numbers, should not be included in videos, recordings, written descriptions, photographs, and pedigrees unless the information is essential for scientific purposes and you have obtained written informed consent for publication in print and electronic form from the patient (or parent, guardian or next of kin where applicable). If such consent is made subject to any conditions, The Editor and Publisher must be made aware of all such conditions. Written consents

must be provided to the Editorial Office on request. Even where consent has been given, identifying details should be omitted if they are not essential. If identifying characteristics are altered to protect anonymity, such as in genetic pedigrees, authors should provide assurance that alterations do not distort scientific meaning and editors should so note. If consent for publication has not been obtained, personal details of patients included in any part of the paper and in any supplementary materials (including all illustrations and videos) must be removed before submission.

Registration of clinical trials

Registration in a public trials registry is a condition for publication of clinical trials in this journal in accordance with International Committee of Medical Journal Editors recommendations. Trials must register at or before the onset of patient enrolment. The clinical trial registration number should be included at the end of the abstract of the article. A clinical trial is defined as any research study that prospectively assigns human participants or groups of humans to one or more health-related interventions to evaluate the effects of health outcomes. Health-related interventions include any intervention used to modify a biomedical or health-related outcome (for example drugs, surgical procedures, devices, behavioural treatments, dietary interventions, and process-of-care changes). Health outcomes include any biomedical or health-related measures obtained in patients or participants, including pharmacokinetic measures and adverse events. Purely observational studies (those in which the assignment of the medical intervention is not at the discretion of the investigator) will not require registration.

RESEARCH DATA

This journal encourages and enables you to share data that supports your research publication where appropriate, and enables you to interlink the data with your published articles. Research data refers to the results of observations or experimentation that validate research findings. To facilitate reproducibility and data reuse, this journal also encourages you to share your software, code, models, algorithms, protocols, methods and other useful materials related to the project. Below are a number of ways in which you can associate data with your article or make a statement about the availability of your data when submitting your manuscript. If you are sharing data in one of these ways, you are encouraged to cite

the data in your manuscript and reference list. Please refer to the “References” section for more information about data citation. For more information on depositing, sharing and using research data and other relevant research materials, visit the research data page. Data linking

If you have made your research data available in a data repository, you can link your article directly to the dataset. Elsevier collaborates with a number of repositories to link articles on ScienceDirect with relevant repositories, giving readers access to underlying data that gives them a better understanding of the research described. There are different ways to link your datasets to your article. When available, you can directly link your dataset to your article by providing the relevant information in the submission system. For more information, visit the database linking page .For supported data repositories a repository banner will automatically appear next to your published article on ScienceDirect. In addition, you can link to relevant data or entities through identifiers within the text of your manuscript, using the following format: Database: xxxx (e.g., TAIR: AT1G01020; CCDC: 734053; PDB: 1XFN).

Mendeley Data

This journal supports Mendeley Data, enabling you to deposit any research data (including raw and processed data, video, code, software, algorithms, protocols, and methods) associated with your manuscript in a free-to-use, open access repository. Before submitting your article, you can deposit the relevant datasets to Mendeley Data. Please include the DOI of the deposited dataset(s) in your main manuscript file. The datasets will be listed and directly accessible to readers next to your published article online.

For more information, visit the Mendeley Data for journals page.

Data statement

To foster transparency, we encourage you to state the availability of your data in your submission. This may be a requirement of your funding body or institution. If your data is unavailable to access or unsuitable to post, you will have the opportunity to indicate why during the submission process, for example by stating that the research data is confidential. The statement will appear with your published article on ScienceDirect. For more information, visit the Data statement page.

Language Editing Services

Papers will only be accepted when they are written in an acceptable standard of English. Authors, particularly those whose first language is not English, who require information about language editing and copyediting services pre- and post-submission should visit <http://webshop.elsevier.com/languageservices/translationservices> or visit our Support Center for more information. Please note, Elsevier neither endorses nor takes responsibility for any products, goods or services offered by outside vendors through our services or in any advertising. For more information please refer to our Terms and Conditions.

Article Types

The following contributions will be accepted for publication. Please take careful note of the maximum length where applicable. Overlength articles will be returned to the authors without peer review:

- editorials (commissioned by the editor)
- clinical papers: no more than 3000 words and 30 references
- research papers: no more than 3000 words and 40 references
- review papers - no limit on length or number of references
- technical notes (surgical techniques, new instruments, technical innovations) - no more than 1500 words, 10 references and 2 figures
- case reports - no more than 1500 words, 10 references and 2 figures
- book reviews
- letters to the editor - please see detailed guidelines provided at the end of the main guide for authors
- IAOMS announcements
- general announcements.

Please note: Case reports will be considered for publication only if they add new information to the existing body of knowledge or present new points of view on known diseases.

All authors must have contributed to the paper, not necessarily the patient treatment. Technical notes and case reports are limited to a maximum of 4 authors, in exceptional circumstances, 5.

Criteria for Publication

Papers that will be considered for publication should be:

- focused

- based on a sound hypothesis and an adequate investigation method analysing a statistically relevant series, leading to relevant results that back the conclusion
- well written in simple, scientific English grammar and style
- presented with a clear message and containing new information that is relevant for the readership of the journal
- Note the comment above relating to case reports.
- Please include a paragraph in your cover letter where you explain what is new about your study and why it will have an impact on your field of research.

Following peer-review, authors are required to resubmit their revised paper within 3 months; in exceptional circumstances, this timeline may be extended at the editor's discretion.

Presentation of Manuscripts

General points

Papers should be submitted in journal style. Failure to do so will result in the paper being immediately returned to the author and may lead to significant delays in publication. Spelling may follow British or American usage, but not a mixture of the two. Papers should be double-spaced with a margin of at least 3 cm all round. Each line must be numbered.

Format

Observational or Case Cohort Studies, as well as Case Series must be presented in conformance with STROBE guidelines: <http://www.strobe-statement.org>

Randomized Controlled Trials must be presented in conformance with CONSORT guidelines: <http://www.consort-statement.org>

Systematic Reviews and Meta-Analyses must be presented according to PRISMA guidelines: <http://www.prisma-statement.org>

Papers should be set out as follows, with each section beginning on a separate page:

- title page
- abstract
- text
- acknowledgements
- references
- tables
- captions to illustrations.

Please note that the qualifications of the authors will not be included in the published paper and should not be listed anywhere on the manuscript.

Title page

The title page should give the following information:

- title of the article

- full name of each author
- name and address of the department or institution to which the work should be attributed
- name, address, telephone and fax numbers, and e-mail address of the author responsible for correspondence and to whom requests for offprints should be sent
- sources of support in the form of grants
- key words.

If the title is longer than 40 characters (including spaces), a short title should be supplied for use in the running heads.

Abstract

200 words maximum. Do not use subheadings or abbreviations; write as a continuous paragraph. Must contain all relevant information, including results and conclusion.

Text

Please ensure that the text of your paper conforms to the following structure: Introduction, Materials and Methods, Results, Discussion. There is no separate Conclusion section.

Introduction

- Present first the nature and scope of the problem investigated
- Review briefly the pertinent literature
- State the rationale for the study
- Explain the purpose in writing the paper
- State the method of investigation and the reasons for the choice of a particular method
- ; Should be written in the present tense

Materials and Methods

- Give the full details, limit references• Should be written in the past tense•
 Include exact technical specifications, quantities and generic names• Limit
 the number of subheadings, and use the same in the results section• Mention
 statistical method• Do not include results in this section

Results

- Do not describe methods
- Present results in the past tense
- Present representations rather than endlessly repetitive data
- Use tables where appropriate, and do not repeat information in the text

Discussion

- Discuss - do not recapitulate results
- Point out exceptions and lack of correlations. Do not try to cover up or 'fudge' data
- Show how results agree/contrast with previous work
- Discuss the implications of your findings
- State your conclusions very clearly

Headings: Headings enhance readability but should be appropriate to the nature of the paper. They should be kept to a minimum and may be removed by the Editors. Normally only two categories of headings should be used: major ones should be typed in capital letters; minor ones should be typed in lower case (with an initial capital letter) at the left hand margin.

Quantitative analysis: If any statistical methods are used, the text should state the test or other analytical method applied, basic descriptive statistics, critical value obtained, degrees of freedom, and significance level, e.g. (ANOVA, $F=2.34$; $df=3,46$; $P<0.001$). If a computer data analysis was involved, the software package should be mentioned. Descriptive statistics may be presented in the form of a table, or included in the text.

Abbreviations, symbols, and nomenclature: Only standardized terms, which have been generally accepted, should be used. Unfamiliar abbreviations must be defined when first used. For further details concerning abbreviations, see Baron DN, ed. Units, symbols, and abbreviations. A guide for biological and medical editors and authors, London, Royal Society of Medicine, 1988 (available from The Royal Society of Medicine Services, 1 Wimpole Street, London W1M 8AE, UK).

The minus sign should be -.

If a special designation for teeth is used, a note should explain the symbols. Scientific names of organisms should be binomials, the generic name only with a capital, and should be italicised in the typescript. Microorganisms should be named according to the latest edition of the Manual of Clinical Microbiology, American Society of Microbiology.

Drugs: use only generic (non-proprietary) names in the text. Suppliers of drugs used may be named in the Acknowledgments section. Do not use 'he', 'his' etc where the sex of the person is unknown; say 'the patient' etc. Avoid inelegant alternatives such as 'he/she'. Patients should not be automatically designated as 'she', and doctors as 'he'.

References

The journal's reference style has changed. References should be numbered consecutively throughout the article, beginning with 1 for the first-cited reference. References should be listed at the end of the paper in the order in which they appear in the text (not listed alphabetically by author and numbered as previously).

The accuracy of references is the responsibility of the author. References in the text should be numbered with superscript numerals inside punctuation: for example "Kenneth and Cohen¹⁴ showed..."; "each technique has advantages and disadvantages⁵⁻¹³." Citations in the text to papers with more than two authors should give the name of the first author followed by "et al."; for example: "Wang et al³⁷ identified..."

All references cited in the text must be included in the list of references at the end of the paper. Each reference listed must include the names of all authors. Please see section "Article Types" for guidance on the maximum number of reference for each type of article.

Titles of journals should be abbreviated according to Index Medicus (see www.nlm.nih.gov.uk) . When citing papers from monographs and books, give the author, title of chapter, editor of book, title of book, publisher, place and year of publication, first and last page numbers. Internet pages and online resources may be included within the text and should state as a minimum the author(s), title and full URL. The date of access should be supplied and all URLs should be checked again at proof stage.

Data References This journal encourages you to cite underlying or relevant datasets in your manuscript by citing them in your text and including a data reference in your Reference List. Data references should include the following elements: author name(s), dataset title, data repository, version (where available), year, and global persistent identifier. Add [dataset] immediately before the reference so we can properly identify it as a data reference. The [dataset] identifier will not appear in your published article.

Examples:

Journal article: Halsband ER, Hirshberg YA, Berg LI. Ketamine hydrochloride in outpatient oral surgery. *J Oral Surg* 1971; 29: 472-476.

When citing a paper which has a Digital Object Identifier (DOI), use the following style: Toschka H, Feifel H. Aesthetic and functional results of harvesting radial forearm flap. *Int J Oral Maxillofac Surg* 2001; 30: 45-51. doi: 10.1054/ijom.2000.0005

Book/monograph: Costich ER, White RP. *Fundamentals of oral surgery*. Philadelphia: WB Saunders, 1971: 201-220.

Book chapter: Hodge HC, Smith FA. Biological properties of inorganic fluorides. In: Simons JH, ed.: *Fluorine chemistry*. New York: Academic Press, 1965: 135.

Internet resource: International Committee of Medical Journal Editors. Uniform requirements for manuscripts submitted to biomedical journals. <http://www.icmje.org> [Accessibility verified March 21, 2008]

Please note you can only include up to a maximum of 6 tables and/ or figures within your article.

Tables

Tables should be used only to clarify important points. Double documentation in the form of tables and figures is not acceptable. Tables should be numbered consecutively with Arabic numerals. They should be double spaced on separate pages and contain only horizontal rules. Do not submit tables as photographs. A short descriptive title should appear above each table, with any footnotes suitably identified below. Care must be taken to ensure that all units are included. Ensure that each table is cited in the text.

Figures

All illustrations (e.g. graphs, drawings or photographs) are considered to be figures, and should be numbered in sequence with Arabic numerals. Each figure should have a caption, typed double-spaced on a separate page and numbered correspondingly. The minimum resolution for electronically generated figures is 300 dpi.

Line illustrations: All line illustrations should present a crisp black image on an even white background (127 x 178 mm (5 x 7 in), or no larger than 203 x 254 mm (8 x 10

in). The size of the lettering should be appropriate, taking into account the necessary size reduction.

Photographs and radiographs: Photomicrographs should show magnification and details of any staining techniques used. The area(s) of interest must be clearly indicated with arrows or other symbols.

Colour images are encouraged, but the decision whether an illustration is accepted for reproduction in colour in the printed journal lies with the editor-in-chief. Figures supplied in colour will appear in colour in the online version of the journal.

Size of photographs: The final size of photographs will be: (a) single column width (53 mm), (b) double column width (110 mm), (c) full page width (170 mm). Photographs should ideally be submitted at the final reproduction size based on the above figures.

Funding body agreements and policies

Elsevier has established agreements and developed policies to allow authors who publish in Elsevier journals to comply with potential manuscript archiving requirements as specified as conditions of their grant awards. To learn more about existing agreements and policies please visit <http://www.elsevier.com/fundingbodies>

Proofs

One set of page proofs in PDF format will be sent by e-mail to the corresponding author, which they are requested to correct and return within 48 hours. Elsevier now sends PDF proofs which can be annotated; for this you will need to download Adobe Reader version 7 available free from <http://www.adobe.com/products/acrobat/readstep2.html>. Instructions on how to annotate PDF files will accompany the proofs. The exact system requirements are given at the Adobe site: <http://www.adobe.com/products/acrobat/acrrsystemreqs.html#70win>. If you do not wish to use the PDF annotations function, you may list the corrections (including replies to the Query Form) and return to Elsevier in an e-mail. Please list your corrections quoting line number. If, for any reason, this is not possible, then mark the

corrections and any other comments (including replies to the Query Form) on a printout of your proof and return by fax, or scan the pages and e-mail, or by post.

Please use this proof only for checking the typesetting, editing, completeness and correctness of the text, tables and figures. Significant changes to the article as accepted for publication will only be considered at this stage with permission from the Editor. We will do everything possible to get your article published quickly and accurately. Therefore, it is important to ensure that all of your corrections are sent back to us in one communication: please check carefully before replying, as inclusion of any subsequent corrections cannot be guaranteed. Proofreading is solely your responsibility. Note that Elsevier may proceed with the publication of your article if no response is received.

Offprints

The corresponding author will be provided, at no cost, with a customize Share Link providing 50 days free access to the final published version of the article on Science Direct. The Share Link can be used for sharing the article via any communication channel, including email and social media. For an extra charge, paper offprints can be ordered via the offprint order form which is sent once the article is accepted for publication. Both corresponding and co-authors may order offprints at any time via Elsevier's Webshop. Corresponding authors who have published their article open access do not receive a Share Link as their final version of the article is available open access on Science Direct and can be shared through the article DOI link.

Accepted Articles

For the facility to track accepted articles and set email alerts to inform you of when an article's status has changed, visit: <http://authors.elsevier.com/TrackPaper.html> There are also detailed artwork guidelines, copyright information, frequently asked questions and more. Contact details for questions arising after acceptance of an article, especially those related to proofs, are provided after registration of an article for publication.

Instructions for Letters to the Editor

The IJOMS welcomes Letters to the Editor. To facilitate submission of the highest quality of Letters to the Editor, the following guidelines should be followed:

1. Letters are meant to be focus pieces and, therefore, are limited to no more than 600 words, 6 references and a maximum of 2 figures. One reference should include a reference to the IJOMS article being addressed.
2. It is recommended that you limit your letter to one or two important and critical points to which you wish to provide a clear and precise discussion regarding the previously published article.
3. One should support all assertion by peer review literature which should be a primary research or large clinical studies rather than a case report.
4. Please include any financial disclosures at the end of the letter. This would include the potential conflicts of interest not just related to the specific content of your letter but also the content of the IJOMS article and other related areas.
5. Please recognize that letters that are essentially in agreement with the author's findings and offer no additional insights provide little new information for publication. Likewise, letters that highlight the writer's own research or are otherwise self promotional will receive a low publication priority.
6. There may be a need for additional editing. Should editing be required the letter will be sent back to the author for final approval of the edited version.
7. It is important to use civil and professional discourse. It is not advisable that one adopt a tone that may be misconstrued to be in anyway insulting.
8. Finally, it is not advisable to provide a letter that is anecdotal. While personal experiences can have great value in patient care, it is generally not strong evidence to be placed in a letter to the editor.

ANEXO B - PARECER DO COMITÊ DE ÉTICA DA UFJF



PARECER CONSUBSTANCIADO DO CEP

DADOS DO PROJETO DE PESQUISA

Título da Pesquisa: Avaliação das mudanças morfológicas na via aérea superior de pacientes retrognatas submetidos à cirurgia ortognática com avanços maxilomandibulares

Pesquisador: Bruno Salles Sotto Maior

Área Temática:

Versão: 2

CAAE: 70597917.0.0000.5147

Instituição Proponente: FACULDADE DE ODONTOLOGIA

Patrocinador Principal: Financiamento Próprio

DADOS DO PARECER

Número do Parecer: 2.195.162

Apresentação do Projeto:

Trata-se de um estudo clínico retrospectivo, a ser composto por 40 pacientes provenientes do serviço de Cirurgia e Traumatologia Bucomaxilofacial de um Hospital Universitário Estadual do Rio de Janeiro. Serão avaliadas as mudanças da morfologia da via aérea destes pacientes no período pré-operatório (T0) e pós-operatório imediato de no máximo 10 dias (T1), através de exame de tomografia computadorizada de feixe cônico, que foram necessários para o correto planejamento e avaliação do tratamento cirúrgico executado. Os exames serão avaliados em uma Universidade Pública de Juiz de Fora, através do software de imagem Dolphin Imaging (Dolphin Imaging and Management Solutions, Chatsworth, Calif., EUA), sem a necessidade de qualquer identificação dos pacientes para a realização da pesquisa. Apresentação do projeto esta clara, detalhada de forma objetiva, descreve as bases científicas que justificam o estudo, de acordo com as atribuições definidas na Resolução CNS 466/12 de 2012, item III.

Objetivo da Pesquisa:

Objetivo Primário:

O objetivo deste estudo retrospectivo será avaliar a alteração da área em milímetros quadrados (mm²) vista no plano sagital, do volume em milímetros cúbicos (mm³) da via aérea como um todo, a área em milímetros² na vista axial no ponto de maior constrição ântero-posterior e a mudança

Endereço: JOSE LOURENCO KELMER S/N

Bairro: SAO PEDRO

CEP: 36.036-900


UF: MG

Município: JUIZ DE FORA

Telefone: (32)2102-3788

Fax: (32)1102-3788

E-mail: cep.propesq@ufff.edu.br



ântero-posterior do osso hioide que está diretamente relacionado a via aérea superior.

Objetivo Secundário:

Avaliar se há diferença significativa entre os grupos G1 e G2 na alteração da área (milímetros²), no volume (milímetros³) e na área da região de maior constrição na vista axial em milímetros².

O Objetivo da pesquisa está bem delineado, apresenta clareza e compatibilidade com a proposta, tendo adequação da metodologia aos objetivos pretendido, de acordo com as atribuições definidas na Norma Operacional CNS 001 de 2013, item 3.4.1 - 4.

Avaliação dos Riscos e Benefícios:


Os riscos envolvidos na pesquisa consistem em riscos mínimos e restringe-se ao sigilo a identificação e as informações referentes ao participante, no entanto, todos os cuidados serão tomados para preservar a sua identidade. A forte associação entre pacientes classe II esqueléticos com retrusão mandibular e a via aérea mais estreita, fazem da cirurgia ortognática um procedimento com potencial de mudança na morfologia desta área, através do avanço das estruturas para correção da harmonia facial e oclusal. O estreitamento da via aérea está relacionado a distúrbios sistêmicos e piora na qualidade de vida de determinado grupo de pessoas, podendo estar fortemente associado como um fator de risco para o desenvolvimento de doenças sistêmicas como a síndrome da apneia obstrutiva do sono. Desta forma é importante avaliar, a alteração na via aérea após o avanço mandibular, e a magnitude do movimento necessário para que ocorram tais mudanças de forma significativas, auxiliando no planejamento dos cirurgiões para pacientes que apresentam características de via aérea estreita. Riscos e benefícios descritos em conformidade com a natureza e propósitos da pesquisa. O risco que o projeto apresenta é caracterizado como risco mínimo, considerando que os indivíduos não sofrerão qualquer dano ou sofrerão prejuízo pela participação ou pela negação de participação na pesquisa e benefícios esperados estão adequadamente descritos. A avaliação dos Riscos e Benefícios estão de acordo com as atribuições definidas na Resolução CNS 466/12 de 2012, itens III; III.2 e V.

Comentários e Considerações sobre a Pesquisa:

O projeto está bem estruturado, delineado e fundamentado, sustenta os objetivos do estudo em sua metodologia de forma clara e objetiva, e se apresenta em consonância com os princípios éticos norteadores da ética na pesquisa científica envolvendo seres humanos elencados na resolução 466/12 do CNS e com a Norma Operacional Nº 001/2013 CNS.

Considerações sobre os Termos de apresentação obrigatória:

Endereço: JOSE LOURENCO KELMER S/N
Bairro: SAO PEDRO **CEP:** 36.036-900
UF: MG **Município:** JUIZ DE FORA
Telefone: (32)2102-3788 **Fax:** (32)1102-3788 **E-mail:** cep.propesq@ufjf.edu.br



O protocolo de pesquisa está em configuração adequada, apresenta FOLHA DE ROSTO devidamente preenchida, com o título em português, identifica o patrocinador pela pesquisa, estando de acordo com as atribuições definidas na Norma Operacional CNS 001 de 2013 item 3.3 letra a; e 3.4.1 item 16. Apresenta o TERMO DE DISPENSA DO TCLE de acordo com a Resolução CNS 466 de 2012, item: IV.8. O Pesquisador apresenta titulação e experiência compatível com o projeto de pesquisa, estando de acordo com as atribuições definidas no Manual Operacional para CPEs. Apresenta DECLARAÇÃO de infraestrutura e de concordância com a realização da pesquisa de acordo com as atribuições definidas na Norma Operacional CNS 001 de 2013 item 3.3 letra h.

Conclusões ou Pendências e Lista de Inadequações:

Diante do exposto, o projeto está aprovado, pois está de acordo com os princípios éticos norteadores da ética em pesquisa estabelecido na Res. 466/12 CNS e com a Norma Operacional Nº 001/2013 CNS. Data prevista para o término da pesquisa: Junho de 2018.

Considerações Finais a critério do CEP:

Diante do exposto, o Comitê de Ética em Pesquisa CEP/UFJF, de acordo com as atribuições definidas na Res. CNS 466/12 e com a Norma Operacional Nº001/2013 CNS, manifesta-se pela APROVAÇÃO do protocolo de pesquisa proposto. Vale lembrar ao pesquisador responsável pelo projeto, o compromisso de envio ao CEP de relatórios parciais e/ou total de sua pesquisa informando o andamento da mesma, comunicando também eventos adversos e eventuais modificações no protocolo.

Este parecer foi elaborado baseado nos documentos abaixo relacionados:

Tipo Documento	Arquivo	Postagem	Autor	Situação
Informações Básicas do Projeto	PB_INFORMAÇÕES_BÁSICAS_DO_PROJETO_843615.pdf	31/07/2017 15:17:55		Aceito
Projeto Detalhado / Brochura Investigador	ProjetoCaioCEP.docx	31/07/2017 15:17:36	Caio Bellini Lovisi	Aceito
Outros	CurriculoCaio.pdf	01/07/2017 17:23:02	Caio Bellini Lovisi	Aceito
Outros	Curriculo_Neuza.pdf	01/07/2017 17:22:48	Caio Bellini Lovisi	Aceito
Outros	Curriculo_BrunoSallesSottoMaior.pdf	01/07/2017 17:22:23	Caio Bellini Lovisi	Aceito

Endereço: JOSE LOURENCO KELMER S/N

Bairro: SAO PEDRO

CEP: 36.036-900

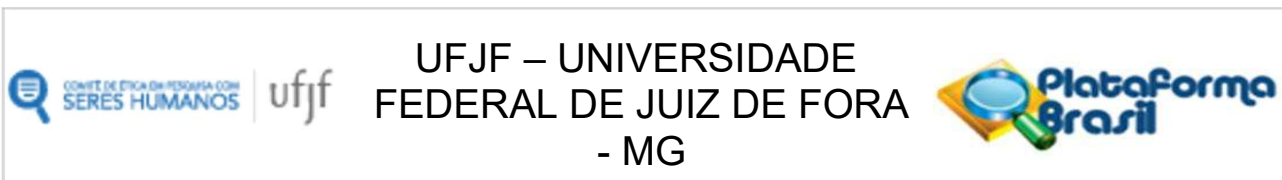
UF: MG

Município: JUIZ DE FORA

Telefone: (32)2102-3788

Fax: (32)1102-3788

E-mail: cep.propesq@uffj.edu.br



Continuação do Parecer: 2.195.162

Declaração de Instituição e Infraestrutura	Declaracao_Infraestrutura_UERJ.pdf	19/04/2017 22:53:17	Caio Bellini Lovisi	Aceito
Declaração de Instituição e Infraestrutura	Declaracao_Infraestrutura_UFJF.pdf	19/04/2017 22:53:04	Caio Bellini Lovisi	Aceito
TCLE / Termos de Assentimento / Justificativa de Ausência	Dispensa_do_TCLE.pdf	19/04/2017 22:51:44	Caio Bellini Lovisi	Aceito
Folha de Rosto	Folha_de_Rosto_CEP.pdf	19/04/2017 22:50:09	Caio Bellini Lovisi	Aceito

Situação do Parecer:

Aprovado

Necessita Apreciação da CONEP:

Não

JUIZ DE FORA, 01 de Agosto de 2017

Assinado por:
Patrícia Aparecida Fontes Vieira
(Coordenador)

Endereço: JOSE LOURENCO KELMER S/N

Bairro: SAO PEDRO

CEP: 36.036-900

UF: MG

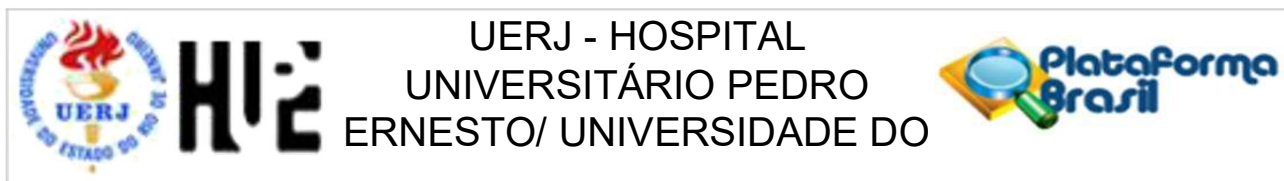Município: JUIZ DE FORA

Telefone: (32)2102-3788

Fax: (32)1102-3788

E-mail: cep.propesq@uff.edu.br

ANEXO C - PARECER DO COMITÊ DE ÉTICA DA UERJ / HUPE



PARECER CONSUBSTANCIADO DO CEP

Elaborado pela Instituição Coparticipante

DADOS DO PROJETO DE PESQUISA

Título da Pesquisa: Avaliação das mudanças morfológicas na via aérea superior de pacientes retrognatas submetidos à cirurgia ortognática com avanços maxilomandibulares

Pesquisador: Bruno Salles Sotto Maior

Área Temática:

Versão: 1

CAAE: 70597917.0.3001.5259

Instituição Proponente: Hospital Universitário Pedro Ernesto/UERJ

Patrocinador Principal: Financiamento Próprio

DADOS DO PARECER

Número do Parecer: 2.450.559

Apresentação do Projeto:

Trata-se de um estudo clínico retrospectivo, a ser composto por 40 pacientes provenientes do serviço de Cirurgia e Traumatologia Bucomaxilofacial do Hospital Universitário Pedro Ernesto da Universidade Estadual do Rio de Janeiro (UERJ), que foram tratados cirurgicamente para correção de deformidade dentofacial do tipo classe II de Angle (retrognatas). Serão avaliadas as mudanças da morfologia da via aérea destes pacientes no

período pré-operatório (T0) e pós-operatório imediato de no máximo 10 dias (T1), através de exame de tomografia computadorizada de feixe cônico, que foram necessários para o correto planejamento e avaliação do tratamento cirúrgico executado. Os exames serão avaliados na Faculdade de Odontologia da Universidade Federal de Juiz de Fora, através do software de imagem Dolphin Imaging (Dolphin Imaging and Management Solutions, Chatsworth, Calif., EUA), sem a necessidade de qualquer identificação dos pacientes para a realização da pesquisa.

Objetivo da Pesquisa:

O objetivo deste estudo retrospectivo será avaliar a alteração da área em milímetros quadrados (mm²) vista no plano sagital, do volume em milímetros cúbicos (mm³) da via aérea como um todo, a área em milímetros² na vista axial no ponto de maior restrição ântero-posterior e a mudança ântero-posterior do osso hioide que está diretamente relacionado a via aérea superior.

Endereço: Avenida 28 de Setembro 77 - Térreo

Bairro: Vila Isabel

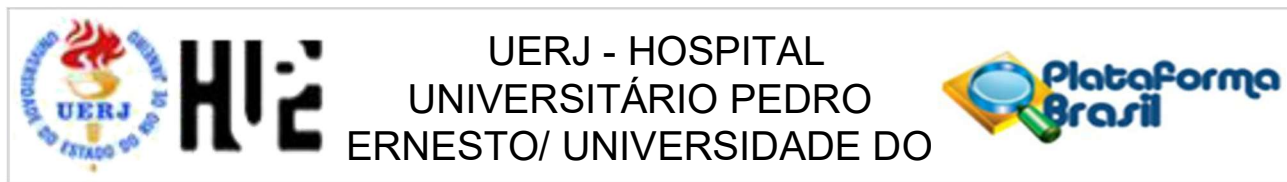CEP: 20.551-030

UF: RJ

Município: RIO DE JANEIRO

Telefone: (21)2868-8253

E-mail: cep.hupe.interno@gmail.com



Avaliação dos Riscos e Benefícios:

Riscos:

Os riscos envolvidos na pesquisa consistem em riscos mínimos e restringe-se ao sigilo a identificação e as informações referentes ao participante,

no entanto, todos os cuidados serão tomados para preservar a sua identidade.

Benefícios:

A forte associação entre pacientes classe II esqueléticos com retrusão mandibular e a via aérea mais estreita, fazem da cirurgia ortognática um procedimento com potencial de mudança na morfologia desta área, através do avanço das estruturas para correção da harmonia facial e oclusal.

O estreitamento da via aérea está relacionado a distúrbios sistêmicos e piora na qualidade de vida de determinado grupo de pessoas, podendo estar

fortemente associado como um fator de risco para o desenvolvimento de doenças sistêmicas como a síndrome da apneia obstrutiva do sono.

Desta forma é importante avaliar, a alteração na via aérea após o avanço mandibular, e a magnitude do movimento necessário para que ocorram

tais mudanças de forma significativas, auxiliando no planejamento dos cirurgiões para pacientes que apresentam características de via aérea estreita.

Comentários e Considerações sobre a Pesquisa:

O objetivo deste estudo retrospectivo, será a avaliação da mudança da morfologia da via aérea em pacientes que foram submetidos a avanço

mandibular para correção de deformidade dentofacial do tipo classe II de Angle. Serão selecionados pacientes aleatoriamente e de forma

randomizada que foram submetidos a cirurgia ortognática com avanço de mandíbula para correção estética e funcional (oclusão) entre o período de

janeiro de 2012 e janeiro de 2016 e divididos em 2 grupos G1 (avanços de mandíbula menores que 5 milímetros) e G2 (avanços de mandíbula

maiores que 5 milímetros). Previamente ao procedimento cirúrgico foi realizado exame tomográfico de feixe cônico em posição natural de cabeça

para o planejamento virtual dos movimentos cirúrgicos necessários. O exame foi repetido com os mesmos equipamentos no pós-operatório imediato

entre 7 e 10 dias de pós-operatório, com intuito de avaliar os cortes cirúrgicos e a fixação

Endereço: Avenida 28 de Setembro 77 - Térreo

Bairro: Vila Isabel

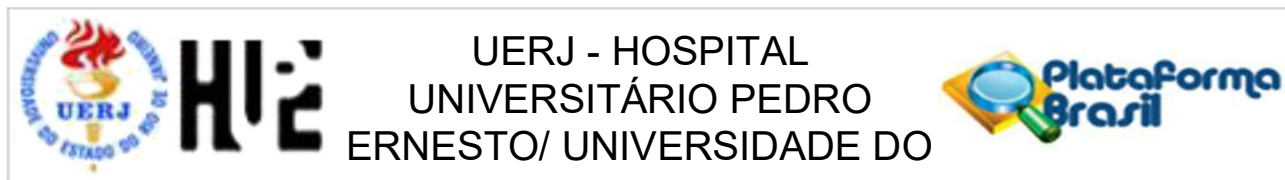
CEP: 20.551-030

UF: RJ

Município: RIO DE JANEIRO

Telefone: (21)2868-8253

E-mail: cep.hupe.interno@gmail.com



realizada. Para a avaliação da mudança na morfologia da via aérea, será realizada a sobreposição dos exames tomográficos pré e pós-operatórios utilizando a ferramenta "Superimpose Tool" do software de manipulação de imagem Dolphin Imaging (Dolphin Imaging and Management Solutions, Chatsworth, Calif., EUA). Após a sobreposição das tomografias será avaliada o avanço mandibular obtido durante a cirurgia para correta divisão dos grupos, e através da ferramenta "Airway/Sinus Avaliation Tool" verificar a mudança da área em milímetros quadrados (mm^2) e o volume em milímetros cúbico (mm^3) no período T0 e T1. Todos os dados coletados serão analisados estatisticamente com significância de 5% utilizando teste t de Student para amostras pareadas.

Considerações sobre os Termos de apresentação obrigatória:

Todos os documentos de apresentação obrigatória foram enviados a este Comitê, estando dentro das boas práticas e apresentando todas dados necessários para apreciação ética. A pesquisa está bem estruturada e o referencial teórico e metodológico estão explicitados, demonstrando aprofundamento e conhecimento necessários para sua realização. As referências estão adequadas e a pesquisa é exequível.

Recomendações:

Não há

Conclusões ou Pendências e Lista de Inadequações:

O projeto pode ser realizado da forma como está apresentado. Diante do exposto e à luz da Resolução CNS nº466/2012, o projeto pode ser enquadrado na categoria – APROVADO.

Considerações Finais a critério do CEP:

Tendo em vista a legislação vigente, o CEP recomenda ao Pesquisador: Comunicar toda e qualquer alteração do projeto e no termo de consentimento livre e esclarecido, para análise das mudanças; Informar imediatamente qualquer evento adverso ocorrido durante o desenvolvimento da pesquisa; O Comitê de Ética solicita a V. S^a., que encaminhe relatórios parciais de andamento a cada 06 (seis) Meses da pesquisa e ao término, encaminhe a esta comissão um sumário dos resultados do projeto; Os dados individuais de

Endereço: Avenida 28 de Setembro 77 - Térreo

Bairro: Vila Isabel

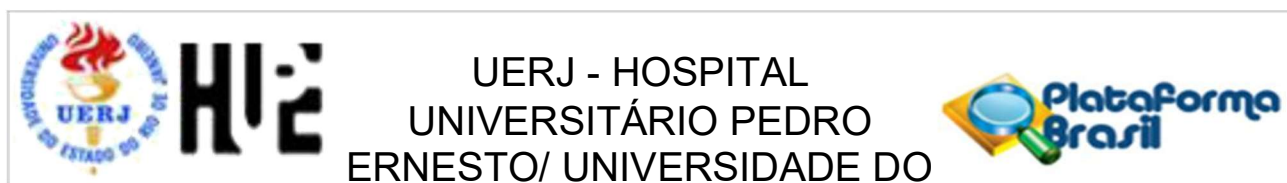
CEP: 20.551-030

UF: RJ

Município: RIO DE JANEIRO

Telefone: (21)2868-8253

E-mail: cep.hupe.interno@gmail.com



todas as etapas da pesquisa devem ser mantidos em local seguro por 5 anos para possível auditoria dos órgãos competentes.

Este parecer foi elaborado baseado nos documentos abaixo relacionados:

Tipo Documento	Arquivo	Postagem	Autor	Situação
Informações Básicas do Projeto	PB_INFORMAÇÕES_BÁSICAS_DO_PROJETO_843615.pdf	31/07/2017 15:17:55		Aceito
Projeto Detalhado / Brochura Investigador	ProjetoCaioCEP.docx	31/07/2017 15:17:36	Caio Bellini Lovisi	Aceito
Informações Básicas do Projeto	PB_INFORMAÇÕES_BÁSICAS_DO_PROJETO_843615.pdf	01/07/2017 17:27:32		Aceito
Projeto Detalhado / Brochura Investigador	ProjetoCaioCEP.docx	01/07/2017 17:27:11	Caio Bellini Lovisi	Aceito
Outros	CurriculoCaio.pdf	01/07/2017 17:23:02	Caio Bellini Lovisi	Aceito
Outros	Curriculo_Neuza.pdf	01/07/2017 17:22:48	Caio Bellini Lovisi	Aceito
Outros	Curriculo_BrunoSallesSottoMaior.pdf	01/07/2017 17:22:23	Caio Bellini Lovisi	Aceito
Informações Básicas do Projeto	PB_INFORMAÇÕES_BÁSICAS_DO_PROJETO_843615.pdf	20/04/2017 17:03:36		Aceito
Declaração de Instituição e Infraestrutura	Declaracao_Infraestrutura_UERJ.pdf	19/04/2017 22:53:17	Caio Bellini Lovisi	Aceito
Declaração de Instituição e Infraestrutura	Declaracao_Infraestrutura_UFJF.pdf	19/04/2017 22:53:04	Caio Bellini Lovisi	Aceito
TCLE / Termos de Assentimento / Justificativa de Ausência	Dispensa_do_TCLE.pdf	19/04/2017 22:51:44	Caio Bellini Lovisi	Aceito
Folha de Rosto	Folha_de_Rosto_CEP.pdf	19/04/2017 22:50:09	Caio Bellini Lovisi	Aceito

Situação do Parecer:

Aprovado

Necessita Apreciação da CONEP:

Não

Endereço: Avenida 28 de Setembro 77 - Térreo

Bairro: Vila Isabel

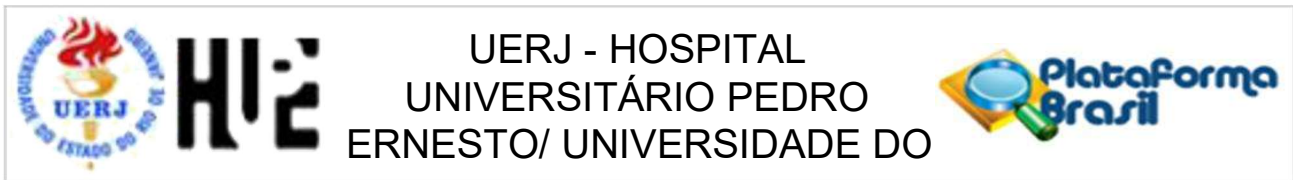
CEP: 20.551-030

UF: RJ

Município: RIO DE JANEIRO

Telefone: (21)2868-8253

E-mail: cep.hupe.interno@gmail.com



Continuação do Parecer: 2.450.559

RIO DE JANEIRO, 20 de Dezembro de 2017

Assinado por:
DENIZAR VIANNA ARAÚJO
(Coordenador)

Endereço: Avenida 28 de Setembro 77 - Térreo

Bairro: Vila Isabel

CEP: 20.551-030

UF: RJ

Município: RIO DE JANEIRO

Telefone: (21)2868-8253

E-mail: cep.hupe.interno@gmail.com