

UNIVERSIDADE FEDERAL DE JUIZ DE FORA
FACULDADE DE ODONTOLOGIA
PROGRAMA DE PÓS-GRADUAÇÃO EM ODONTOLOGIA

MARAÍSA APARECIDA PINTO RESENDE

**QUALIDADE DE REBORDOS ALVEOLARES PRESERVADOS E SUA
INFLUÊNCIA NA ESTABILIDADE PRIMÁRIA E SECUNDÁRIA DO IMPLANTE:
RESULTADOS PRELIMINARES DE UM ESTUDO CLÍNICO-
MICROTOMOGRÁFICO CONTROLADO E RANDOMIZADO.**

JUIZ DE FORA

2018

MARAÍSA APARECIDA PINTO RESENDE

**QUALIDADE DE REBORDOS ALVEOLARES PRESERVADOS E SUA
INFLUÊNCIA NA ESTABILIDADE PRIMÁRIA E SECUNDÁRIA DO IMPLANTE:
RESULTADOS PRELIMINARES DE UM ESTUDO CLÍNICO-
MICROTOMOGRÁFICO CONTROLADO E RANDOMIZADO.**

Dissertação de mestrado apresentada ao Programa de Pós-graduação em Clínica Odontológica, da Faculdade de Odontologia da Universidade Federal de Juiz de Fora, como requisito parcial para obtenção do título de Mestre em Clínica Odontológica. Área de concentração em Clínica Odontológica.

Orientador: Prof. Dr. Bruno Salles Sotto-Maior

Coorientadora: Prof^a. Dr^a. Neuza Maria Souza Picorelli Assis

JUIZ DE FORA

2018

Ficha catalográfica elaborada através do programa de geração automática da Biblioteca Universitária da UFJF, com os dados fornecidos pelo(a) autor(a)

Resende, Maraísa Aparecida Pinto.

Qualidade de rebordos alveolares preservados e sua influência na estabilidade primária e secundária do implante: resultados preliminares de um estudo clínico-microtomográfico controlado e randomizado / Maraísa Aparecida Pinto Resende. -- 2018.

57 p. : il.

Orientador: Bruno Salles Sotto-Maior

Coorientadora: Neuza Maria Souza Picorelli Assis

Dissertação (mestrado acadêmico) - Universidade Federal de Juiz de Fora, Faculdade de Odontologia. Programa de Pós Graduação em Clínica Odontológica, 2018.


1. Osso. 2. Implantes dentais. 3. Microtomografia computadorizada. 4. Análise de frequência de ressonância. I. Sotto Maior, Bruno Salles, orient. II. Assis, Neuza Maria Souza Picorelli, coorient. III. Título.

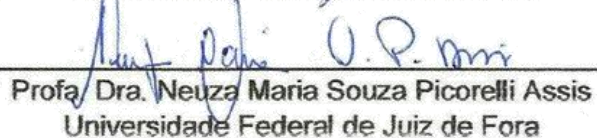
MARAÍSA APARECIDA PINTO RESENDE


**QUALIDADE DE REBORDOS ALVEOLARES PRESERVADOS E SUA
INFLUÊNCIA NA ESTABILIDADE PRIMÁRIA E SECUNDÁRIA DO
IMPLANTE: RESULTADOS PRELIMINARES DE UM ESTUDO CLÍNICO
MICROTOMOGRÁFICO CONTROLADO E RANDOMIZADO.**


Dissertação de mestrado apresentada ao Programa de Pós-graduação em Clínica Odontológica, da Faculdade de Odontologia da Universidade Federal de Juiz de Fora, como requisito parcial para obtenção do título de Mestre em Clínica Odontológica. Área de concentração em Clínica Odontológica.

Aprovada em 19 de setembro de 2018


Prof. Dr. Bruno Salles Sotto-Maior
Universidade Federal de Juiz de Fora


Profa. Dra. Neuz Maria Souza Picorelli Assis
Universidade Federal de Juiz de Fora


Prof. Dr. Gustavo Davi Rabelo
Universidade Federal de Juiz de Fora


Prof. Dr. Augusto César Sette-Dias
Centro Universitário Newton Paiva

Agradecimentos Especiais

Agradeço primeiramente a Deus, por me dar saúde, força, disposição e a oportunidade de chegar até aqui.

Ao meu orientador Prof. Dr. Bruno Salles Sotto-Maior pelo apoio, dedicação e providenciais orientações para que esse trabalho pudesse ser realizado.

À minha coorientadora Prof^a. Dr^a. Neuza Maria Souza Picorelli Assis pelo agradável convívio e por sempre dividir comigo seus ensinamentos. Agradeço pela confiança depositada na minha pessoa. A minha eterna admiração, respeito, carinho e gratidão.

Profa. Dra. Priscila Barbosa Ferreira Soares e ao Pós-Doc Pedro Henrique Justino Oliveira Limirio, da Universidade Federal de Uberlândia, pelo auxílio na aquisição das imagens de microtomografia computadorizada.

Ao Prof. Dr. Gustavo Davi Rabelo pela constante disponibilidade, auxílio na interpretação das imagens microtomográficas e realização da estatística.

À empresa Neodent® que disponibilizou todos os implantes e componentes protéticos que foram utilizados nesta pesquisa, fator incontestável para o sucesso dos resultados obtidos e aqui apresentados.

O presente trabalho foi realizado com apoio da Coordenação de Aperfeiçoamento de Pessoal de Nível Superior – Brasil (CAPES) – Código de Financiamento 001.

Agradecimentos

Ao Prof. Dr. Augusto César Sette-Dias pela leitura crítica deste trabalho e por ter se tornado, além de um excelente professor, um amigo, que sempre torceu por mim e inclusive me incentivou na realização deste mestrado.

Aos professores Prof. Dr. Breno Nogueira e ao Prof. Dr. Eduardo Vilella pela convivência maravilhosa nas clínicas de cirurgia.

Aos Funcionários da Pós-Graduação, por estarem sempre disponíveis em todos os momentos.

Aos amigos que conquistei no decorrer deste curso, especialmente Lucas Lactim, Isabella Francisquini, Thais Pires, Caio Bellini, Molise Fagundes, cuja ajuda foi essencial na realização das cirurgias, contribuindo para o excelente andamento desta pesquisa.

Aos pacientes que participaram da pesquisa, por toda paciência e disponibilidade em todas as etapas clínicas.

Enfim, é por dever de justiça que agradeço a todos que de alguma forma contribuíram para a realização deste trabalho.

RESUMO

O objetivo deste estudo clínico controlado randomizado microtomográfico foi comparar a qualidade óssea entre dois métodos diferentes de preservação do rebordo alveolar e avaliar as estabilidades primária e secundária dos implantes instalados nessas regiões. Vinte pacientes foram divididos aleatoriamente em dois grupos de tratamento após uma única extração dentária. Dez alvéolos foram enxertados com fosfato de cálcio bifásico (SBC, n = 10) associado a um retalho de tecido conjuntivo subepitelial pediculado para o fechamento primário. Dez alvéolos foram selados com uma restauração provisória de pântico ovóide (PROV, n = 10) sem material de enxertia. Após 12 meses, 9 pacientes perderam-se no acompanhamento e 11 pacientes receberam implantes dentários. As biópsias ósseas foram avaliadas por microtomografia computadorizada (8 μ m), quanto às características do osso trabecular. Valores de torque de inserção (ITV) e quociente inicial de estabilidade do implante (ISQI) foram registrados no momento da instalação dos implantes. O ISQ também foi registrado aos 7 dias, 30 dias e 60 dias pós-operatórios. Todos os onze pacientes tiveram os implantes osseointegrados sem intercorrências. O grupo PROV apresentou trabéculas mais espessas ($0,17 \pm 0,03$) em relação ao grupo SBC ($0,11 \pm 0,03$) ($p = 0,03$). O osso trabecular foi mais anisotrópico em PROV ($0,3 \pm 0,08$) comparado com SBC ($0,1 \pm 0,07$) ($p = 0,01$). O grupo PROV apresentou menor superfície óssea ($26,02 \pm 10,36$) que o grupo SBC ($40,09 \pm 10,94$) ($p = 0,05$). Além disso, o PROV apresentou ISQ inicial mais alto ($72,3 \pm 21$) em comparação com o SBC ($67 \pm 3,9$) ($p = 0,05$). O osso trabecular revelou diferenças na microarquitetura entre os dois métodos de preservação do rebordo alveolar e ambos os métodos foram satisfatórios para a instalação do implante e resultaram em altos valores de ITV e ISQ.

Palavras-chave: Osso, implantes dentais, microtomografia computadorizada, análise de frequência de ressonância.

ABSTRACT

This randomized controlled clinical microtomographic trial aimed to compare the bone quality between two different methods of alveolar ridge preservation and to evaluate the primary and secondary implant stability. Twenty patients were randomly divided into two groups following a single tooth extraction: SBC group (n=10), sockets were grafted with alloplastic biphasic calcium phosphate and a pedicle subepithelial connective tissue flap was used for primary closure; and PROV group (n=10), sockets were sealed with an ovate pontic provisional restoration. After 12 months, 11 patients received dental implants, with nine patients lost to follow-up. Bone biopsies were evaluated by microcomputed-tomography (8 μ m) to determine cancellous bone characteristics. Insertion torque values (ITV) and initial implant stability quotient (ISQI) were recorded at installation. The ISQ was also recorded 7, 30 and 60 days after the implant was installed. All implants showed uneventful osseointegration. The PROV group presented thicker trabeculae (0.17 ± 0.03) compared to the SBC group (0.11 ± 0.03 ; p 0.03). Trabeculae bone was more anisotropic in the PROV group (0.3 ± 0.08) compared with the SBC group (0.1 ± 0.07 ; p 0.01). The PROV group presented less bone surface (26.02 ± 10.36) than the SBC group (40.09 ± 10.94 ; p 0.05). Also, PROV showed higher ISQI (72.3 ± 21) than SBC (67 ± 3.9 ; p 0.05). The characteristics of the trabecular bone differed between the two alveolar ridge preservation methods and the both preservation methods gave satisfactory results with regard to implant placement, and both resulted in high values for ITV and ISQ.

Keywords: Bone, dental implants, microcomputed tomography, resonance frequency analysis.

LISTA DE ILUSTRAÇÕES

Figura 1	- Procedimento cirúrgico do Grupo SBC	14
Figura 2	- Procedimento cirúrgico do Grupo PRO	15
Figura 3	- Exame tomográfico pré-operatório	15
Figura 4	- Coleta das amostras ósseas	16
Figura 5	- Protocolo cirúrgico de fresagem	17
Figura 6	- Protocolo de inserção dos implantes	17
Figura 7	- Componente protético e SmartPeg®	18
Figura 8	- Leitura do ISQ	18
Figura 9	- Dispositivo Osttel™ ISQ	19
Figura 10	- Etapa final da cirurgia	19
Figura 11	- Radiografia periapical pós-operatória	20
Figura 12	- Imagem microtomográfica da amostra óssea	21
Figura 13	- Diferenciação dos voxels para delinear tecido ósseo e biomaterial	22

SUMÁRIO

1 Introdução	10
2 Proposição	12
3 Materiais e métodos	13
3.1 Desenho do estudo	13
3.2 Participantes	13
3.3 Intervenções	14
3.4 Avaliação da estabilidade primária dos implantes	15
3.5 Avaliação microtomográfica	20
3.6 Análise dos resultados	22
4 Artigo	24
5 Considerações finais	42
Anexo A – Carta de aprovação do comitê de Ética	44
Anexo B – Registro da Pesquisa no <i>Clinial Trials</i>	48
Anexo C – Normas da revista	53
Anexo D – Carta de submissão do artigo	58

1 INTRODUÇÃO

Após a extração dentária, o osso alveolar residual sofre remodelação tridimensional rápida com altas taxas de reabsorção óssea. Esta condição pode interferir na instalação do implante dentário, uma vez que a crista reabsorvida não acomoda adequadamente os implantes, comprometendo a estética e a função da restauração protética (ARTZI, TAL e DAYAN, 2000; ARAÚJO e LINDHE, 2005; ARAÚJO e LINDHE, 2011). Vários métodos têm sido apresentados com o objetivo de prevenir a contração volumétrica dos alvéolos, com redução tanto da perda de tecidos duros quanto dos tecidos moles (DAHLIN *et al.*, 1998; MCALLISTER e HAGHIGHAT, 2007; FICKL *et al.*, 2008; ARAÚJO, LINDER e LINDHE, 2009; MARDAS, CHADHA e DONOS, 2010). A preservação da crista alveolar mantém as dimensões ósseas, facilita a colocação do implante em uma posição protética adequada e proporciona ótima estética com boa previsibilidade no sucesso da osteointegração (MARDAS *et al.*, 2011; ARAÚJO *et al.*, 2015; NATTO *et al.*, 2017).

Muitos estudos recentes têm focado nas diferentes técnicas de preservação do rebordo alveolar por análises tomográficas, histológicas e/ou histomorfométricas (FICKL *et al.*, 2008; MARDAS *et al.*, 2010; MARDAS *et al.*, 2011; VIGNOLETTI *et al.*, 2012; WANG *et al.*, 2016; BAUMER *et al.*, 2017; JAIN *et al.*, 2017; NATTO *et al.*, 2017). Essas metodologias revelaram considerável heterogeneidade, com avaliação de diferentes materiais de enxerto, técnicas cirúrgicas e em diferentes períodos de tempo (FERNANDEZ DE GRADO *et al.* 2018). Em um estudo recente, uma restauração provisória imediata de pântico ovóide instalado em um alvéolo intacto sem material de enxerto foi usado para avaliar as mudanças dimensionais que ocorrem e os resultados forneceram validação na preservação do contorno do tecido com esta técnica (BAKSHI *et al.*, 2018).

Independentemente do método de preservação utilizado, o objetivo final é a instalação do implante em volume ósseo adequado (SJÖSTRÖM *et al.*, 2005). Não está claro se os diferentes tipos de preservação do rebordo alveolar irão interferir na qualidade do osso e na estabilidade do implante. Alguns autores sugeriram que a estabilidade primária seria um fator crítico para prever se um implante será bem sucedido ou não (RASMUSSEN *et al.*, 1999; BECKER *et al.*, 2005; HERRERO-CLIMENT *et al.*, 2013; FU *et al.*, 2017).

Até o presente momento, não foi encontrado na literatura pesquisada um trabalho que avalie a qualidade do osso trabecular por meio de microtomografia computadorizada de amostras ósseas colhidas de regiões preservadas; e, se o método de preservação pode interferir na estabilidade primária e secundária através de análise de frequência de ressonância dos implantes. Desta maneira, é de suma importância uma pesquisa tanto sobre técnicas e materiais efetivos para preservação alveolar, como também uma pesquisa sobre o prosseguimento com a reabilitação do espaço preservado.

2 PROPOSIÇÃO

O presente estudo tem os objetivos de avaliar as estabilidades primária e secundária de implantes instalados em alvéolos tratados por duas técnicas diferentes de preservação e também, avaliar a qualidade óssea trabecular dessas regiões.

3 MATERIAIS E MÉTODOS

O presente estudo clínico foi aprovado pelo Comitê de Ética em Pesquisa da Universidade Federal de Juiz de Fora sob o parecer de nº 1.731.395 (Anexo 1), inscrito na plataforma *Clinical Trials*, sendo atribuído o número de identificação NCT03166475 (Anexo 2). Este trabalho foi escrito e formatado segundo as diretrizes estabelecidas pelo CONSORT (*Consolidated Standarts of Reporting Trials*).

3.1 DESENHO DO ESTUDO

Este estudo foi conduzido como uma pesquisa clínica-microtomográfica controlada e randomizada, sendo as etapas realizadas na Faculdade de Odontologia da Universidade Federal de Juiz de Fora e no Centro de Pesquisa em Biomecânica, Biomateriais e Biologia Celular (CPBio) da Faculdade de Odontologia da Universidade Federal de Uberlândia.

3.2 PARTICIPANTES

Foram incluídos vinte participantes consecutivos que se apresentaram a Faculdade de Odontologia da Universidade Federal de Juiz de Fora com indicação de extração de pré-molares ou incisivos superiores, por motivo de fratura radicular, cáries extensas que não permitissem tratamento restaurador e/ou com prognóstico endodôntico desfavorável. O dente a ser extraído devia apresentar integridade alveolar e a presença dos dois dentes adjacentes hígidos. Os pacientes deveriam ser sistemicamente saudáveis, ou, se com presença de doença, a mesma devia estar controlada e maiores de dezoito anos.

Foram excluídos a nível sistêmico os pacientes tabagistas e com doenças descontroladas. Em nível local foram excluídos os dentes que apresentavam recessão gengival, lesão endodôntica aguda no dente indicado para extração ou nas áreas vizinhas e com alvéolos severamente reabsorvidos, ou que no momento da cirurgia a tábua óssea vestibular ou palatina fosse removida junto com o dente.

Todos os participantes assinaram um Termo de Consentimento Livre e Esclarecido (TCLE), concordando em participar de forma voluntária dessa pesquisa.

3.3 INTERVENÇÕES

Os pacientes foram alocados aleatoriamente em dois grupos de acordo com os seguintes tratamentos: Grupo SBC: Preenchimento do alvéolo com enxerto de Bone Ceramic® (Straumann AG, Basel, Suíça) e recobrimento do mesmo com deslize de retalho palatino segundo o técnica de Khoury et al. (2000) (Figura 1).

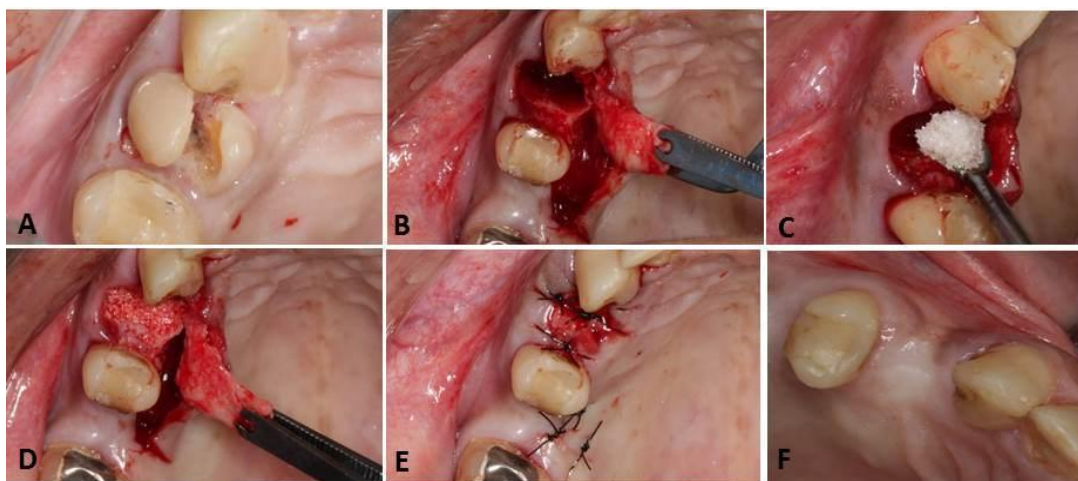


Figura 1 – Procedimento cirúrgico do Grupo SBC. (A) Dente a ser extraído. (B) Descolamento total do retalho e início da divisão do retalho. (C) Preenchimento do alvéolo com BoneCeramic® (Straumann AG, Basel, Suíça). (D) Recobrimento do enxerto com deslize do retalho palatino pediculado. (E) Fechamento por primeira intenção (F) Região cicatrizada no pós-operatório de 12 meses. Fonte: Camila Furtado.

Grupo PROV: Vedamento do alvéolo por um pântico ovóide de resina acrílica (Figura 2). O provisório foi confeccionado de maneira que penetrava 2 a 3 mm no interior do alvéolo, onde ele vedava toda circunferência do alvéolo e era estabilizado lateralmente pelos dentes adjacentes, com fio de aço 0,5 mm e resina composta ou resina acrílica. A oclusão foi ajustada para eliminar todos os contatos nos movimentos excursivos de lateralidade e protrusão.

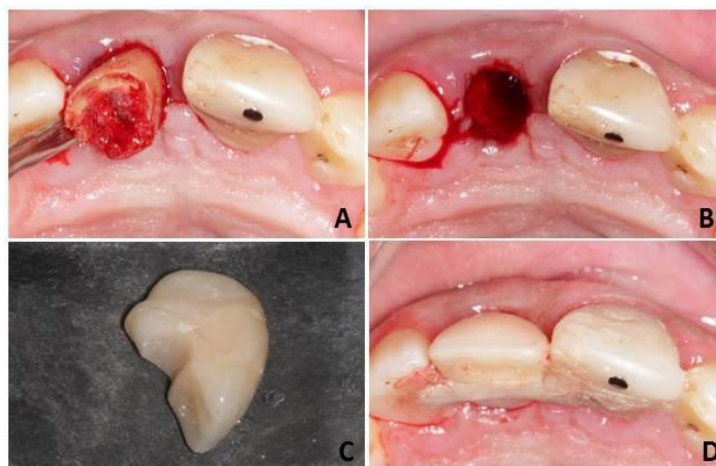


Figura 2 – Procedimento cirúrgico do Grupo PROV. (A) Extração minimamente traumática. (B) Alvéolo preparado para receber o provisório, preenchido apenas de sangue. (C) Provisório no formado ovóide feito de resina acrílica. (D) Provisório em posição esplintado aos dentes adjacentes com fio ortodôntico e resina acrílica Fonte: Camila Furtado.

3.4 AVALIAÇÃO DA ESTABILIDADE PRIMÁRIA DOS IMPLANTES

Todos os pacientes realizaram TCFC com afastamento labial no pré-operatório para avaliar as dimensões dos alvéolos para o planejamento dos implantes. Todas as imagens foram adquiridas pelo tomógrafo I-Cat[®] (Imaging Sciences International, Hatfield, Pensilvânia, EUA), sob o seguinte protocolo: 26,9 s, voxel de 0,25 mm e FOV (field of view) de 7 x 13 cm (Figura 3).

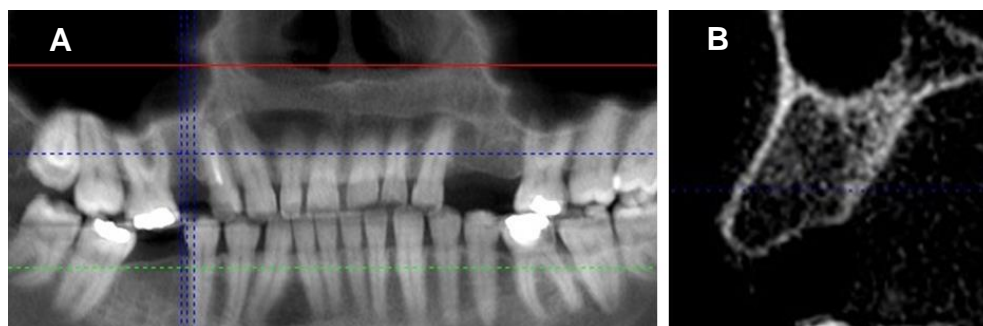


Figura 3 – Exame tomográfico pré-operatório. (A) Corte panorâmico. (B) corte parassagital. Fonte: a autora.

Foi prescrito a todos os pacientes 04 comprimidos de amoxicilina 500 mg, 01 comprimido de dexametasona 4 mg uma hora antes do procedimento cirúrgico (ANDRADE, 2001). Após antissepsia intra e extraoral com clorexidina 0,12% e 2% respectivamente foram colocados os campos cirúrgicos estéreis. A anestesia local foi obtida com uso de lidocaína 2% epinefrina 1:100.000.

Foi coletado o material para análise microtomográfica, que foi removido com uso de broca trefina 2.0 mm de diâmetro (Figura 4). As amostras foram colocadas imersas em um recipiente com solução de formol a 10%.

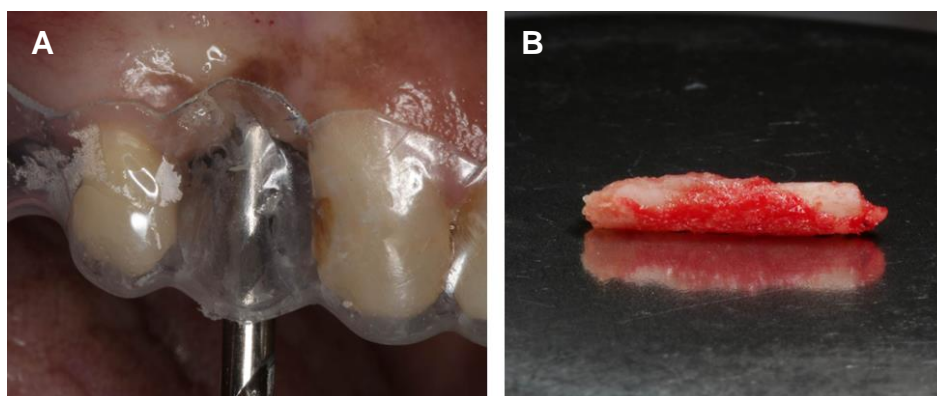


Figura 4 – Coleta das amostras ósseas. (A) Amostra sendo colhida com broca trefina. (B) Amostra removida. Fonte: a autora.

Em seguida foi realizada uma incisão linear sobre o rebordo alveolar na região e descolamento do retalho. Foram utilizados implantes e componentes doados pela empresa Neodent® (Curitiba, PR, Brasil). Os diâmetros utilizados foram de 3,5 x 11,5 mm ou 3,5 x 8 mm, dependendo da altura remanescente do rebordo. O sistema de fresagem e inserção dos implantes seguiu o protocolo preconizado pelo fabricante (Figura 5), exceto pela utilização da trefina como primeira broca. A rotação de perfuração das brocas não ultrapassou 800 rpm, como recomendado para ossos tipo III e IV.

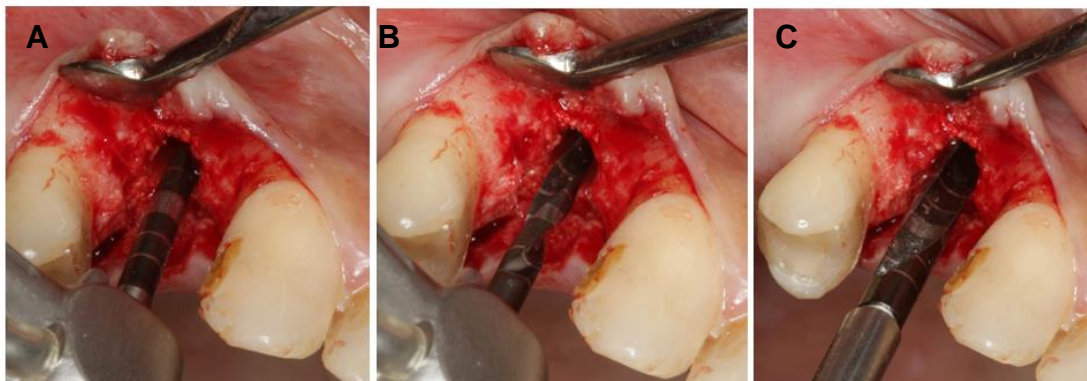


Figura 5 – Protocolo cirúrgico de fresagem. (A) Broca lança. (B) Broca 2.0. (C) Broca 3.5.
Fonte: a autora.

A inserção inicial do implante foi com uso do contra-ângulo a 30 rpm e foi finalizada com uso de torquímetro manual. Foi aferido o torque de inserção (ITV), que não ultrapassou 60 Ncm e o valor foi tabulado (Figura 6),

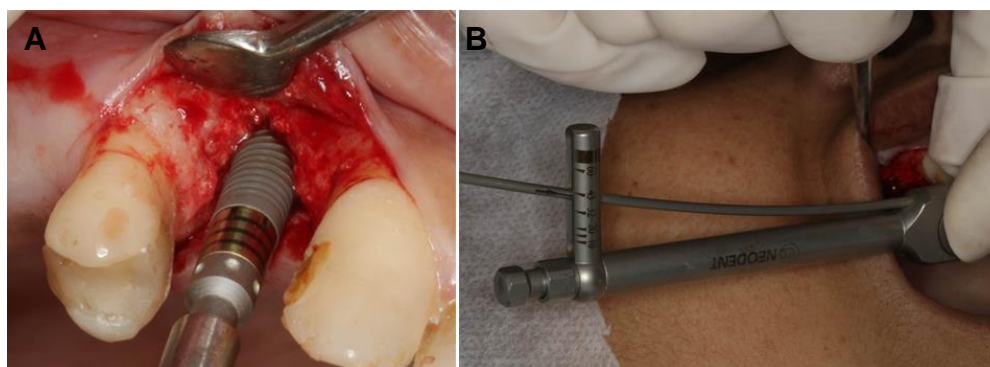


Figura 6 – Protocolo de inserção dos implantes. (A) Inserção inicial do implante com contra ângulo. (B) Inserção final do implante e aferição do torque de inserção.
Fonte: a autora.

O componente protético foi instalado com torque máximo de 20 N e sobre ele foi adaptado o SmartPeg® (Integration Diagnostics AB, Göteborg, Suécia) (Figura 7). Segundo o fabricante, o aparelho gera uma série de sinais com diferentes frequências em Hertz (Hz) e esses valores são imediatamente convertidos em ISQ (Coeficiente da Estabilidade do Implante), proporcionando um monitoramento rápido e exato. A escala de valores lineares do ISQ varia de 1 a 100, sendo que os altos valores de ISQ presume-se alta qualidade na ancoragem

do implante ao osso. A aferição foi realizada nas superfícies vestibular e palatina dos intermediários, ou seja, cada implante foi submetido a 2 leituras (Figura 8). As leituras foram capturadas pelo dispositivo Ostell™ e tabuladas para posterior análise (Figura 9).

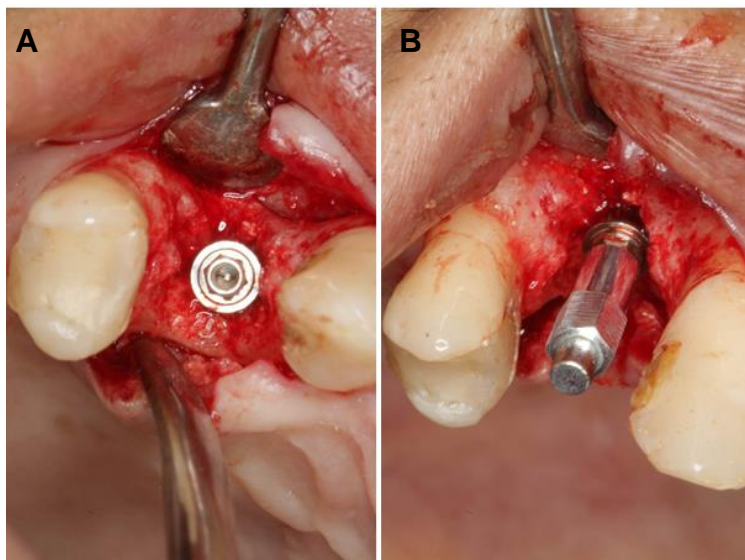


Figura 7 – Componente protético e SmartPeg®. (A) Micro pilar instalado. (B) SmartPeg® adaptado sobre o micro-pilar. Fonte: a autora.

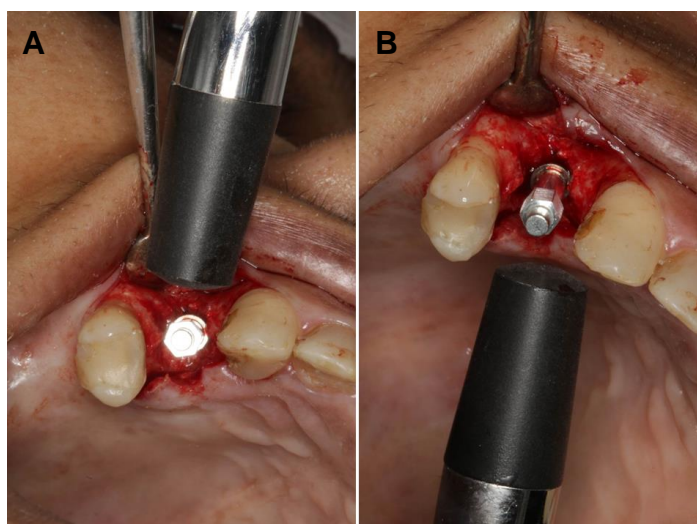


Figura 8 – Leitura do ISQ. (A) Leitura vestibular. (B) Leitura palatina. Fonte: a autora.

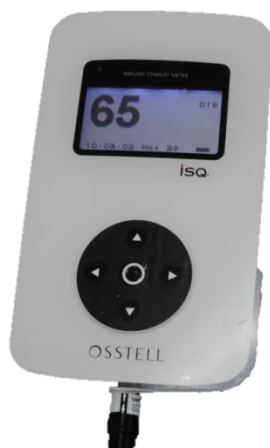

Figura 9 – Dispositivo Osttel™ ISQ. Fonte: a autora.

As medições por meio de AFR foram repetidas nos intervalos de 7 a 10 dias, 30 dias e 60 dias, para avaliação do ISQ no período de osseointegração. Os micro-pilares foram cobertos com os parafusos de proteção do micro-pilar apenas com pressão digital, e, finalmente, a incisão foi suturada (Figura 10).

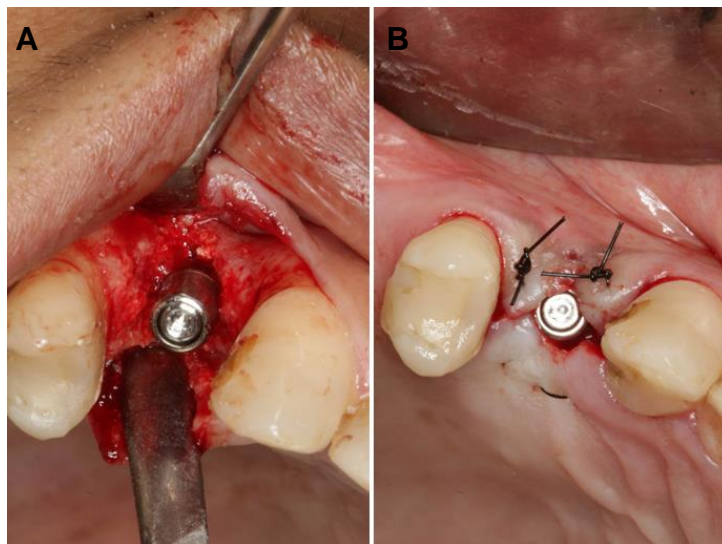


Figura 10 – Etapa final da cirurgia. (A) Parafuso de proteção do micro-pilar em posição. (B) Suturas. Fonte: a autora.

Os pacientes foram orientados quanto aos cuidados pós-operatórios. Foi prescrito nimesulida 100 mg de doze em doze horas por três dias, dipirona sódica

500mg em caso de dor e bochechos com clorexidina 0,12% de doze em doze horas até a remoção das suturas.

Após o ato cirúrgico, foram realizadas radiografias periapicais da região operada para conferir a posição dos implantes (Figura 11).

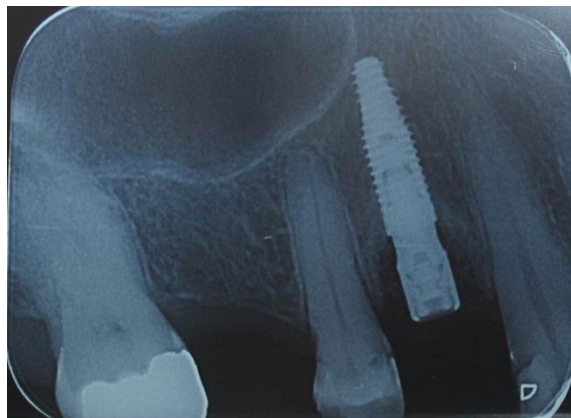


Figura 11 – Radiografia periapical pós-operatória. Fonte: a autora.

3.5 AVALIAÇÃO MICROTOMOGRÁFICA

A MicroCT foi realizada pelo microtomógrafo Skyscan 1172 (Skyscan, Antuérpia, Bélgica) para cada amostra de osso (fonte de energia 92 kV, 120 mA, resolução de 8 μ m). Foi utilizada rotação de 180° e um filtro de alumínio de 0,5 para redução de ruído. A reconstrução foi realizada utilizando software NRecon V 1.4.4 (Skyscan, Antuérpia, Bélgica), com os seguintes parâmetros selecionados: Smoothing = 1, Ring Artifact Correction = 10 e Beam Hardening Correction (%) = 10.

O software CT-An (CTAnalyser, Skyscan, Antuérpia, Bélgica) foi usado para calcular parâmetros morfométricos ósseos para cada volume de interesse (VOI). Neste momento, foi delineada a escolha apenas da área trabecular para análise, excluindo a parte cortical. Desta forma, a microarquitetura óssea de cada amostra foi avaliada na parte trabecular (Figura 12), considerando as características e organização das trabéculas. Ainda, no grupo SBC havia presença de biomaterial em toda região da amostra, que dificultava a delimitação do osso cortical. Portanto,

para minimizar vieses, a avaliação da microarquitetura óssea foi realizada apenas em osso trabecular em ambos os grupos.




Figura 12 – Imagem microtomográfica original da amostra óssea. Fonte: a autora.

Os parâmetros morfométricos ósseos para cada volume de interesse (VOI) foram calculados determinando a região de interesse (ROI) compreendendo todo o volume trabecular, separado manualmente. A parte mais superior (top) da região trabecular era definida, assim como a parte mais inferior (bottom). As ROIs foram delineadas em cortes de forma aleatória, e as demais foram criadas artificialmente pelo processo de interpolação. Ao fim, o conjunto de todas as ROIs eram utilizados para formar o VOI e posteriormente era iniciado o processo de binarização, baseando-se nos histogramas de cada imagem (corte).

Antes da binarização, os limiares de tons de cinza foram escolhidos da seguinte forma: dois para o grupo SBC, sendo um para todo o volume (40, considerando osso + biomaterial) (Figura 13A) e outro (100) para o biomaterial apenas (Figura 13B). E apenas um para o osso no grupo PROV (80) (Figura 13C).

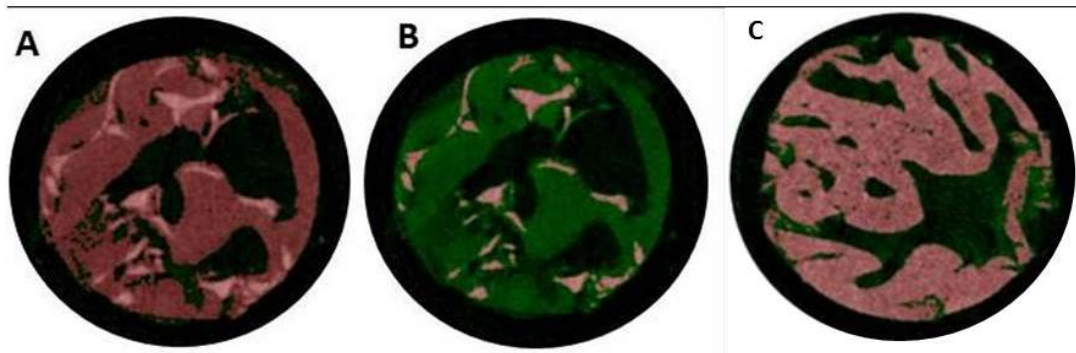


Figura 13 – Diferenciação dos voxels para delinear tecido ósseo e biomaterial. (A) Todo tecido mineral delineado no grupo SBC (osso + BoneCeramic®). (B) Apenas biomaterial delineado no Grupo SBC. (C) Tecido ósseo delineado no grupo PROV. Fonte: a autora.

Os parâmetros analisados foram: densidade do volume ósseo (BV/TV, % - sendo a razão de volume ósseo sobre o tecido total analisado), razão superfície óssea por volume (BS/BV, 1/mm), espessura trabecular (Tb.Th, mm), separação trabecular (Tb.Sp, mm), número trabecular (Tb.N, 1/mm), índice de modelo estrutural (SMI, #), densidade de conectividade (Conn.D, 1/mm³) e grau de anisotropia (DA, #). No que diz respeito aos parâmetros microtomográficos, o índice de modelo estrutural (SMI) é um indicador do formato das trabéculas, o valor varia de 1 a 4, sendo aqueles com o valor mais próximo de 1 apresentam trabéculas mais achatadas (plate like), e um valor mais próximo de 3 apresentam trabéculas mais cilíndricas (rod like). Valores próximos de 4 remetem à caracterização de uma esfera perfeita. O grau de anisotropia (DA) representa uma ferramenta de análise de textura que tem a ver com a organização das trabéculas no espaço. Valores mais próximos de 1 significam maior anisotropia e valores mais próximos de 0 indicam isotropia.

Para a estatística, foram consideradas as medidas de quantidade total (osso e biomaterial) do grupo SBC.

3.6 ANÁLISES DOS RESULTADOS

Dados clínicos e de microCT foram sumarizados em análise descritiva expressa em média e desvio padrão. Análises de correlação foram realizadas para verificar associações entre os parâmetros ósseos trabeculares e a estabilidade do implante (coeficiente de correlação de Pearson). As comparações entre os grupos

PROV e SBC foram avaliadas pelo teste de Mann-Whitney (intervalo de confiança de 95%). A significância estatística foi estabelecida em $p \leq 0,05$. O *GraphPad Prism* 5.0 foi usado para análise de dados.

4 ARTIGO

Title: Quality of preserved alveolar ridges and the influence on primary and secondary implant stability: preliminary results of a controlled and randomized clinical-microtomographic study.

Running-title: Preserved alveolar ridges and implant stability.

Authors' affiliations:

- 1) Maraísa Aparecida Pinto Resende - Master's student, Faculty of Dentistry, Federal University of Juiz de Fora, Juiz de Fora, Minas Gerais, Brazil.
- 2) Gustavo Davi Rabelo - Faculty of Dentistry, Federal University of Juiz de Fora, Juiz de Fora, Minas Gerais, Brazil.
- 3) Priscilla Barbosa Ferreira Soares – Periodontology Department, Faculty of Dentistry, Federal University of Uberlândia, Uberlândia, Minas Gerais, Brazil.
- 4) Karina Lopes Devito – Department of Clinic of Dentistry, Federal University of Juiz de Fora, Juiz de Fora, Minas Gerais, Brazil.
- 5) Neuza Maria Souza Picorelli Assis –Department of Clinic of Dentistry, Faculty of Dentistry, Federal University of Juiz de Fora, Juiz de Fora, Minas Gerais, Brazil.
- 6) Bruno Salles Sotto-Maior – Department of Restorative Dentistry, Faculty of Dentistry, Federal University of Juiz de Fora, Juiz de Fora, Minas Gerais, Brazil.

Corresponding author:

Prof. Dr. Bruno Salles Sotto-Maior
Faculdade de Odontologia – Campus Universitário
Bairro Martelos – Juiz de Fora – MG
CEP: 36036-300
e-mail: brunosottomaior@gmail.com
Telefone/Fax: (32) 2102-3881

Key words: Bone, dental implants, microcomputed tomography, resonance frequency analysis.

Abstract

Objective: This randomized controlled clinical microtomographic trial aimed to compare the bone quality between two different methods of alveolar ridge preservation and to evaluate the primary and secondary implant stability.

Material and methods: Twenty patients were randomly divided into two groups following a single tooth extraction: SBC group (n=10), sockets were grafted with alloplastic biphasic calcium phosphate and a pedicle subepithelial connective tissue flap was used for primary closure; and PROV group (n=10), sockets were sealed with an ovate pontic provisional restoration. After 12 months, 11 patients received dental implants, with nine patients lost to follow-up. Bone biopsies were evaluated by microcomputed-tomography (8 μ m) to determine cancellous bone characteristics. Insertion torque values (ITV) and initial implant stability quotient (ISQ) were recorded at installation. The ISQ was also recorded 7, 30 and 60 days after the implant was installed.

Results: All implants showed uneventful osseointegration. The PROV group presented thicker trabeculae (0.17 ± 0.03) compared to the SBC group (0.11 ± 0.03 ; p 0.03). Trabeculae bone was more anisotropic in the PROV group (0.3 ± 0.08) compared with the SBC group (0.1 ± 0.07 ; p 0.01). The PROV group presented less bone surface (26.02 ± 10.36) than the SBC group (40.09 ± 10.94 ; p 0.05). Also, PROV showed higher ISQ (72.3 ± 21) than SBC (67 ± 3.9 ; p 0.05).

Conclusion: The characteristics of the trabecular bone differed between the two alveolar ridge preservation methods. However, both preservation methods gave satisfactory results with regard to implant placement, and both resulted in high values for ITV and ISQ.

Introduction

After a tooth extraction, the residual alveolar bone undergoes rapid three-dimensional remodeling with high rates of bone resorption. This remodeling may interfere with dental implant installation as the resorbed ridge cannot properly accommodate implants, thereby compromising the esthetics and function of the prosthetic restoration (Artzi, Tal, & Dayan 2000; Araújo & Lindhe 2005; Araújo & Lindhe 2011). Several methods aimed at preventing volumetric contraction of the socket have been proposed, including reducing both hard and soft tissue loss (Dahlin et al. 1998; Mcallister & Haghghat 2007; Fickl et al. 2008; Araújo, Linder, & Lindhe 2009; Mardas, Chadha, & Donos 2010). Preservation of the alveolar ridge maintains bone dimensions and facilitates implant placement in an adequate prosthetic

position. In addition, it proportionates optimal aesthetics with good predictability on osteointegration process (Mardas et al. 2011; Araújo et al. 2015; Natto et al. 2017).

Many recent studies have focused on different alveolar ridge preservation techniques, assessed by tomographic, histological and/or histomorphometric analyses (Fickl et al. 2008; Mardas et al. 2010; Mardas et al. 2011; Vignoletti et al. 2012; Wang et al. 2016; Baumer et al. 2017; Jain et al. 2017; Natto et al. 2017). There is considerable heterogeneity among methodologies with regard to evaluation of different graft materials, surgical techniques and periods of preservation time (Fernandez de Grado et al. 2018). In a recent study, immediate installation of a fixed ovate pontic provisional restoration into an intact extraction socket without grafting was used to evaluate dimensional changes (Bakshi et al. 2018), and the results confirmed preservation of the tissue contour.

Regardless of the preservation method used, the final goal is installation of the implant into bone with adequate volume (Sjöström et al. 2005). It is unclear whether different alveolar ridge preservation techniques influence the bone quality and implant stability. Some authors have suggested that primary stability is a critical factor for predicting whether an implant will be successful or not (Rasmusson et al. 1999; Becker et al. 2005; Herrero-Climent et al. 2013; Fu et al. 2017). Thus, the objective of this study was to evaluate the trabecular bone quality and the - primary and secondary implant stabilities in sites treated with two different alveolar preservation techniques.

Materials and methods

Sample

Twenty patients were enrolled in this randomized controlled clinical trial (NCT 03166475). This study was designed and formatted according to the Consolidated Standards of Reporting Trials (CONSORT) guidelines, and was approved by the research ethics committee (no. 1.731.395). Written informed consent for participation in the study was obtained from all patients. Patients were first evaluated for study eligibility during an initial screening visit. The study subjects were selected based on the following inclusion criteria: no uncontrolled systemic health conditions; the presence of a hopeless tooth (maxillary incisor or premolar) requiring extraction, and the presence of adjacent teeth. The exclusion criteria included smokers, gingival recession, acute endodontic lesion in the tooth indicated for extraction or in neighboring areas, and major loss of the buccal or palatal osseous wall

following the tooth extraction. The subjects were randomly assigned to one of two groups. A balanced randomly permuted block approach was used to prepare the randomization tables in order to avoid unequal balance between the two treatments (Fig. 1).

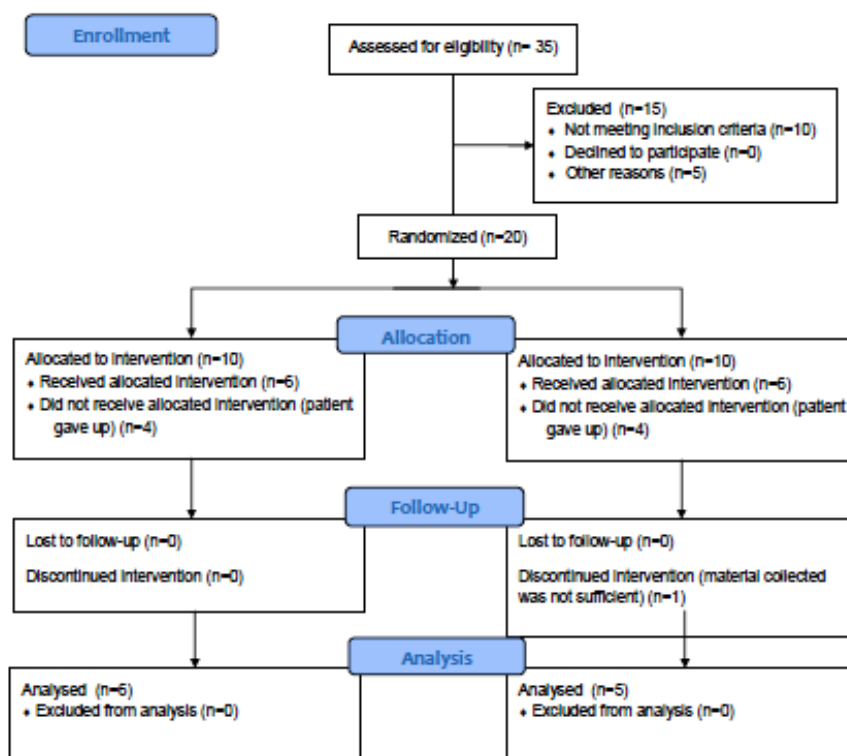


Fig 1 – The Consolidated Standards of Reporting Trials (CONSORT) flow diagram.

At 12 months after the first surgical approach, the patients were submitted to cone-beam computed tomography (CBCT) using an i-CAT scanner (Imaging Sciences International, Hatfield, PA, USA) operating at 120 kVp and 3–8 mA, with a voxel size of 0.25 mm, rotation time of 26.9 s, and field of view of 7×13 cm. The CBCT scans were used to provide qualitative information and support planning for implant insertion.

Surgical procedures

Atraumatic extraction of the incisor or premolar tooth was performed using a peritome and elevators. After extraction, the patients were randomly divided into one of two treatment groups. Ten sockets were grafted with alloplastic biphasic calcium phosphate (granule size 400–1000 μm ; Straumann AG, Basel, Switzerland), and primary closure over the

extraction sockets was achieved using a pedicle subepithelial connective tissue flap (SBC, n = 10) (Khoury et al., 2000) (Fig. 2).

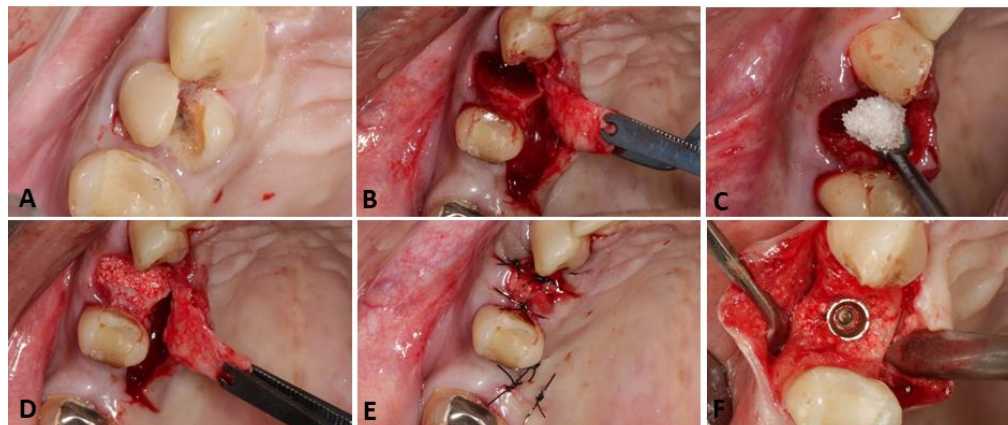


Figure 2 - Surgical procedure for the SBC group. Images A–E depict the first surgical procedure, as follows: (A) tooth to be extracted; (B) minimally traumatic extraction performed with total flap detachment; (C) grafting procedure, with the alveolus filled with BoneCeramic® (Straumann AG, Basel, Switzerland); (D) repositioning of the pediculate palatal flap, and (E) primary closure. For the second surgical procedure, (F) installation of the implant in the preserved alveolus with adequate bone volume.

The other group received no grafting material, and the alveolar socket was sealed with an immediate fixed ovate pontic provisional restoration (PROV, n = 10; Fig. 3). For these patients, a provisional resin-bonded prosthesis with an ovate pontic made of autopolymerized polymethyl methacrylate (PMMA; Alike, USA) was adhesively bonded with flowable composite resin (Beautiful Flor Plus, Shofu, San Marcos, CA, USA) following spot-etching of the adjacent teeth with 37% phosphoric acid (Ultradent; Kerr Corporation, Orange, CA, USA) and application of a light-cured bonding agent (Optibond Solo; Kerr Corporation, Orange, CA, USA) to the adjacent natural teeth. In order to properly support the soft tissue profile, the ovate pontic surface on all cases was finished to have a smooth, convex subgingival contour extending 3 mm apical to the free gingival margin. The polished surface of the pontic was obtained using pumice slurry (coarse/fine grit; Kerr Corporation, Orange, CA, USA). Occlusion was adjusted to eliminate all centric and excursive contacts (Bakshi et al. 2018).

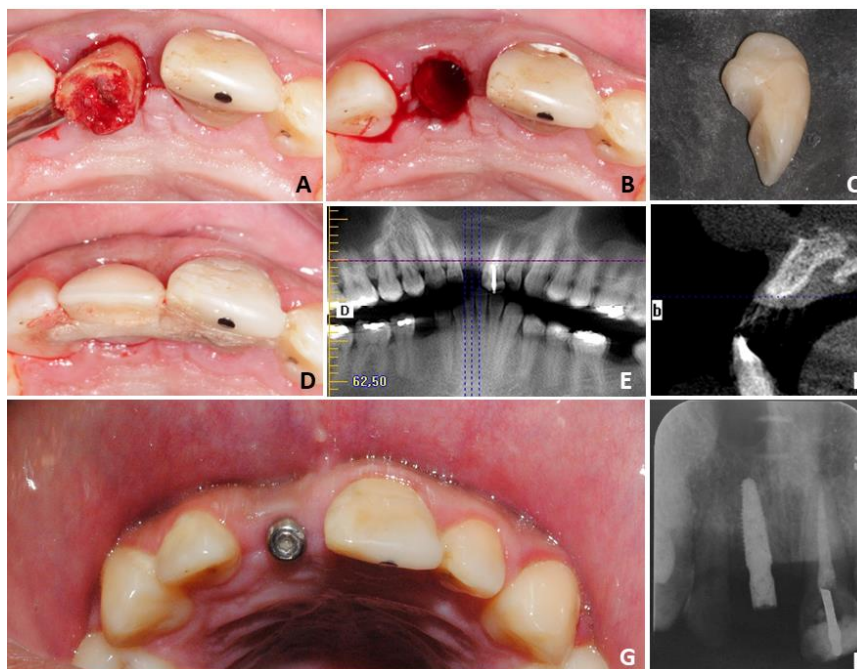


Figure 3 - Surgical procedure for the PROV group. Images A–D depict the first surgical procedure, as follows: (A) minimally traumatic extraction; (B) alveolus prepared to be filled with a blood clot; (C) provisory pontic restoration in an ovoid format made of acrylic resin; and (D) provisory restoration installed and attached to adjacent teeth using an orthodontic appliance and acrylic resin. Images E–H depict the second surgical procedure, as follows: (E) use of CBCT for implant planning, 12 months after the first surgical procedure (panoramic view of the CT scan); (F) sagittal plane in CTBC showing adequate volume of the alveolar ridge; (G) clinical aspect of the implant and micro-abutment, installed in the preserved region; and (H) periapical radiograph confirming the correct positioning of the implant installed in the preserved alveolus.

After 12 months, 11 patients (six in the SBC group and five in the PROV group) were provided Helix Gran Morse implants (Neodent, Curitiba, Brazil) with dimensions of either 3.5×11 mm or 3.5×8 mm. One-stage surgical protocol was used for all surgeries, and there was only one modification of the protocol, which was the use of a 2.0-mm diameter trephine for the first drilling procedure. A bone specimen from each site was

retrieved and maintained in a buffered 10% formalin solution to undergo microCT scans. A surgical micromotor (Neosurg XT plus, Neodent NSK, Curitiba, Brazil) was used for drilling in accordance with the implant manufacturer's recommendation, and implant placement was performed according to standard procedures.

Insertion torque value measurements

The initial torque of the motor was set at 15 Ncm, and the implant was inserted until automatic interruption of the motor (Ribeiro-Rotta et al. 2014). Afterwards, the implant was manually inserted with the manual wrench (Neodent, Curitiba, Brazil). After implant placement, torque value (ITV) measurements were obtained. A micro-abutment was installed with a maximum torque of 20 Ncm.

Resonance frequency analysis

Direct primary and secondary implant stability measurements were obtained by means of the implant stability quotient (ISQ). These data were obtained immediately after implant insertion (ISQ1) and during the osseointegration period at day 7 (ISQ7), 30 (ISQ30) and 60 (ISQ60). To perform these measurements, a wireless device (OsstellTM Mentor; Integration Diagnosis, Gothenburg, Sweden) was used. The resonance frequency analysis (RFA) was obtained in the range of 1100–10,000 Hz with the use of a peg (Smartpeg; Integration Diagnostics AB, Goteburg, Sweden), which was attached to the micro-abutment. The probe of the wireless device was positioned close to the peg in two distinct positions, firstly oriented in the vestibular-oral direction and then in the lingual-oral direction. The resonance frequency value was automatically converted into ISQ, which was presented on the device display and recorded in the patient's file. The higher the ISQ, which ranged from 1 to 100, the higher the stability of the implant (Ribeiro-Rotta et al. 2014).

Measurement of 3D bone microarchitecture

MicroCT was performed by Skyscan 1172 (Skyscan, Antwerp, Belgium) for each bone sample (92 kV, 120 mA, 8 μ m resolution; Fig. 4A and B). A 180° rotation step and a 0.5 mm aluminum filter were used to reduce noise. The bone microarchitecture of each alveolar sample was assessed in the trabecular bone, considering the characteristics and their spatial organization of the trabeculae. Bone morphometric parameters for each volume of interest

(VOI) were calculated by determining the region of interest (ROI) comprising the whole trabecular volume, which was manually separated from the cortices. Prior to binarization, the grayscale thresholds were chosen. There was one threshold for the PROV group (80; Fig. 4C) and two for the SBC group, for which there was one threshold for the whole volume (40, considering bone + biomaterial; Fig. 4D) and another for the biomaterial only (100; Fig. 4E).

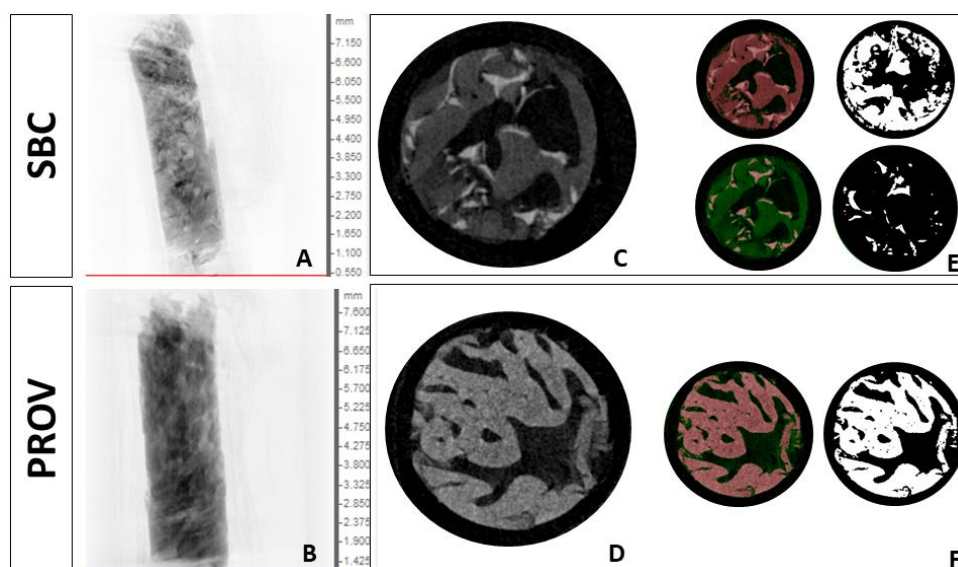


Figure 4 – Microtomography analysis. Original images (Scout view) for (A) the SBC group and (B) the PROV group, showing cortex and trabecular bone in the bone specimen. Images for (C) and (D) show one slice of the trabecular bone in a trans-axial plane within the delimitation of the trabecular bone. Images of the binarization process, with (E) delimitation of the whole material including bone and biomaterial (upper left corner) and the binarized image used for analysis (upper right corner) in the SBC group, and (F) delimitation of the bone tissue in the PROV group (left) and the binarized image (right).

The parameters analyzed included the bone volume density (BV/TV, %), bone surface by volume ratio (BS/BV, 1/mm), trabecular thickness (Tb.Th, mm), trabecular separation (Tb.Sp, mm), trabecular number (Tb.N, 1/mm), structural model index (SMI, #), connectivity density (Conn.Dn, 1/mm³) and degree of anisotropy (DA, #). The measurements for the SBC group comprised the whole volume (bone and biomaterial).

Values obtained for the biomaterial (bone ceramic, BC) alone were also evaluated, and these values were subtracted from those obtained for the whole trabecular volume to determine how much of the whole volume was comprised of the remaining biomaterial.

Data analysis

Clinical and microCT data were summarized by descriptive statistics, expressed as the mean and standard deviation. Correlation analyses were performed to check for associations between trabecular bone parameters and implant stability (Pearson's correlation coefficient). Comparisons between the PROV and SBC groups were assessed by the Mann-Whitney test (95% confidence intervals). Statistical significance was set at $p \leq 0.05$. GraphPad Prism 5.0 was used for all data analyses.

Results

Eight patients dropped out and did not receive the allocated intervention, and one discontinued the intervention because did not present enough bone height to insert the implant without a concomitant sinus lift. In this way, 11 patients received dental implants. There were no interurrences and no signs or symptoms of infection related to the first surgical procedure. At the second visit, CBCT scans and clinical evaluation revealed that 11 patients presented a satisfactory alveolar ridge, with adequate size and thickness necessary for implant placement. The mean height and thickness of the alveolar ridge were 14.8 ± 3.9 and 6.5 ± 0.7 mm for the SBC group and 13.91 ± 3.2 and 5.39 ± 1.6 mm for the PROV group, respectively.

Initial insertion torque values and ISQ values are presented in Table 1. The ISQ values remained higher than 50 for all periods evaluated. All implants were considered osseointegrated. Comparative analyses between the two groups revealed thicker trabeculae ($p = 0.03$), higher anisotropy ($p = 0.01$), reduced bone surface ($p = 0.05$) and higher initial ISQ ($p = 0.05$) in the PROV group compared to the SBC group (Table 1).

Table 1 - Comparisons between the Straumann-bone-ceramic group (SBC) and Provisory group (PROV)

Parameter	SBC	PROV	p
	(n=6)	(n=5)	
	Mean (SD)		
BV/TV	30.49 (20.52)	41.75 (21.04)	0.42
BS/BV	40.09 (10.94)	26.02 (10.36)	0.05*
SMI	1.29 (1.73)	1.97 (2.61)	0.42
Tb.Th	0.11 (0.03)	0.17 (0.03)	0.03*
Tb.N	2.6 (1.8)	2.3 (1.2)	1
Tb.Sp	0.29 (0.14)	0.35 (0.34)	1
Conn.Dn	508.2 (506.2)	332.5 (171.3)	1
DA	0.12 (0.07)	0.30 (0.08)	0.01*
Initial torque	50.0 (12.25)	49.4 (11.70)	0.92
ISQI	67 (3.9)	72.3 (2.1)	0.05*
ISQ7	68 (5.9)	70.8 (2.1)	0.46
ISQ30	67.92 (4.6)	67 (8.43)	0.85
ISQ60	67.75 (5.58)	69.38 (4.49)	0.66

* Significant difference ($p \leq 0.05$). Mann-Whitney test. Bone volume density (BV/TV, %), bone surface by volume ratio (BS/BV, 1/mm), structural model index (SMI, #), trabecular thickness (Tb.Th, mm), trabecular number (Tb.N, 1/mm), trabecular separation (Tb.Sp, mm), connectivity density (Conn.Dn, 1/mm³) and degree of anisotropy (DA, #)

Concerning trabecular microarchitecture, the presence of biomaterial in the SBC group represented 27.25% of the whole volume, 37.43% of the number of trabeculae and 38.6% of the whole surface. Intramethod correlations were found. For MicroCT, BV/TV was correlated with BS/BV, SMI, Tb.N, Tb.Sp and Conn.dn; Conn.Dn was correlated with SMI and Tb.N; Tb.Sp was correlated with Tb.N and SMI; DA was correlated with Tb.Th and BS/BV; SMI was correlated with Tb.N; and BS/BV was correlated with Tb.Th (Table 2). For the clinical parameters, the ISQ at day 30 was correlated with the ISQ at day 60.

Table 2 – Correlation* of clinical and microtomography parameters considering all patients (n=11)

	BS/BV	SMI	Tb.Th	Tb.N	Tb.Sp	Conn.Dn	DA	ISQ60
BV/TV	p 0,00 r ² -0,71	p 0,00 r ² -0,79		p 0,00 r ² 0,84	p 0,01 r ² -0,69	p 0,01 r ² 0,68		
BS/BV			p 0,00 r ² -0,86				p 0,02 r ² -0,62	
SMI				p 0,00 r ² -0,80	p 0,02 r ² 0,63	p 0,02 r ² -0,60		
Tb.Th							p 0,01 r ² 0,65	
Tb.N					p 0,01 r ² -0,65	p 0,00 r ² 0,87		
ISQ30								p 0,04 r ² 0,60

* Results with statistical significance ($p \leq 0.05$) in Pearson correlation test.

Discussion

Two guided bone regeneration procedures were performed to obtain well-preserved alveolar ridges for adequate implant placement. In one group, an ovate pontic provisional restoration was used to seal the alveolar socket without any graft material, and in the other, a biomaterial substitute was inserted. Samples collected before implant placement were evaluated by a high-resolution imaging technique, and the bone quality was assessed through evaluation of the microarchitecture of the trabecular bone. Sealing the socket with a provisional restoration resulted in a higher initial ISQ, thicker trabeculae, more anisotropic bone and less bone surface. There was a correlation between the degree of anisotropy and the stability of the implant.

Few reports in the literature have studied the clinical use of a provisional pontic as an alveolar sealer method for preserving the alveolus (Bakshi et al. 2018; Luckerath, Roder, & Enkling 2018). In addition, there is a lack of information on implant stability and its relationship with the trabecular quality of the preserved ridge, including an absence of substantial data on RFA and micro-tomographic examination of these preserved areas. To our knowledge, no previous studies have compared the ISQ and the microarchitecture of grafted sites containing alloplastic biphasic calcium phosphate with alveolar sites sealed with an ovate pontic provisional restoration.

The PROV group showed thicker trabeculae than the SBC group. Even with the biomaterial representing 27% of the whole volume in the SBC group, trabeculae thickness was higher in the PROV group. A histomorphometric study by Friedmann et al. (2009) found that the percentage of alloplastic biphasic calcium phosphate particles in biopsies ranged from 27.83% to 80.17% after 6 to 10 months postoperative. Mardas et al. (2010) assessed the coronal part of their samples, finding biomaterial particles surrounded by fibroblasts, collagen fibers and blood vessels without any signs of inflammation and no resorption of alloplastic biphasic calcium phosphate particles.

Another indicator of improved bone quality is the degree of anisotropy. The trabecular bone in the PROV group was more anisotropic than the SBC group. Anisotropy represents the orientation of the trabeculae in the space, and high anisotropic distribution of the trabeculae network indicates good bone quality. Anisotropic trabecular bone means that preferential orientation of the trabecular plates is observed along the direction of the strains (Chappard et al. 2008; Irie et al. 2018). Thus, in our understanding, the trabeculae in the PROV group appear to follow an organization pattern that responds to the stimuli received by the site. On the other hand, the SBC group, being more isotropic, may not be influenced by the occlusal load. Although Kesmas et al. (2010) observed that BC particles degraded in a shorter period of time, we noticed the presence of biomaterial particles after a year of grafting in the current study. Thus, the presence of the biomaterial particles may influence the spatial arrangement of the trabeculae.

Interestingly, in addition to thicker trabeculae and greater anisotropy in the PROV group, there was also higher initial stability (ISQI) and lower bone surface values. Lower bone surface could not only be linked to the number of trabeculae, and as SBC group revealed thinner trabeculae and higher values of surface, it can be inferred that trabeculae were longer than the ones in PROV group. A ridge composed of thicker, shorter trabeculae (i.e., less bone surface), also organized according to the strain orientation, might be important to obtain good initial stability. In addition, higher ISQ values are also known to indicate greater bone-implant contact (Açil et al. 2016), represented in our results by thicker trabeculae. The stability of the implants is related to the biomechanical properties and amount of bone that is in contact with the implant (Johansson & Albrektsson 1991).

Stability is a crucial factor for the success of osseointegration. Several studies have evaluated the changes in stability that occur during bone healing (Rasmusson et al. 1999; Becker et al. 2005; Sjöström et al. 2005; Bornstein et al. 2009; Kim et al. 2017; Qabbani et

al. 2017). Removal torque values have been used for many years in preclinical studies to evaluate the quality of osseointegration (Johansson & Albrektsson 1991; Park, Park, & Cho 2016). However, this parameter cannot be used clinically in patients, as it would require removal of the the implant. Meredith et al. (1997) proposed the use of RFA as a noninvasive method to evaluate implant stability. Our methods allowed the association of RFA concomitant with the evaluation of bone quality parameters, which revealed an influence of the quality of the alveolar ridge trabecular bone on the stability of the primary implant. Stability monitoring was performed by RFA at 7, 30 and 60 days, which is sufficient time to monitor the osseointegration process of an implant with a hydrophilic surface. A previous study reported 62% bone implant contact for hydrophilic, moderately rough implant surfaces after 6 weeks (Lang et al. 2011), after which osseointegration may have occurred to a sufficient degree to fully carry the functional load (Rocuzzo et al. 2008).

In relation to the stability of the implant, it is important to note that the ISQ at 30 days observed in the present study was positively correlated with the ISQ at 60 days. Sjöström et al. (2005) previously revealed an increased ISQ over time in ungrafted jaws, with mean ISQ values of 58 ± 4.7 at the time of implant installation and 63 ± 5.6 after 6 months. In a clinical pilot study of grafted maxilla, Rasmusson et al. (1999) also reported an increase in RFA values over time.

Given the importance of implant stability, it is clear that achieving primary stability at the time of insertion is of paramount importance. Therefore, in addition to bone density and the surgical technique employed, it is important to determine the influence of the implant model (Santamaría-Arrieta et al. 2016; Dedigi, Daprile, & Piattelli 2017). In recent years, several modifications in specific surface properties have been investigated with the aim of improving osseointegration of the implants (Ferguson et al. 2006; Lang et al. 2011). An *in vitro* study showed that hydrophilic surfaces support monocyte adhesion, platelet activation and blood clot formation, which are the initial events of osseointegration (Hong, Kurt, & Thor 2013). The high values of ITV and ISQ found in the present study could be explained by the altered implant design and surface treatment, which allowed for excellent primary bone contact and strong anchorage during insertion.

In conclusion, preservation of the alveolar ridge using an ovate pontic provisional restoration resulted in thicker trabeculae, greater anisotropy, higher initial ISQ and less bone surface when compared to the ridge of the grafted site. However, both preservation methods were satisfactory for implant placement, resulting in high values of ITV and ISQ.

Acknowledgements

The authors thanks Neodent® for providing the implants and prosthodontic components for the study. MAPR thanks Lucas Lactim for technical support with obtaining the clinical images. This study was financed in part by the Coordenação de Aperfeiçoamento de Pessoal de Nível Superior – Brasil (CAPES) – Financed code 001.

References

- Açil, Y., Sievers, J., Gulses, A., Ayna, M., Wiltfang, J., Terheyden, H. (2017). Correlation between resonance frequency, insertion torque and bone-implant contact in self-cutting threaded implants. *Odontology* **105**: 347-353.
- Araújo, M.G., Lindhe, J. (2005). Dimensional ridge alterations following tooth extraction. an experimental study in the dog. *Journal of Clinical Periodontology* **32**: 212-218.
- Araújo, M.G., Lindhe, J. (2009). Ridge preservation with the use of Bio-Oss Collagen: a 6-month study in the dog. *Clinical Oral Implants Research* **20**: 433-40.
- Araújo, M.G., Lindhe, J. (2011). Socket grafting with the use of autologous bone: an experimental study in the dog. *Clinical Oral Implants Research* **22**: 9-13.
- Araújo, M.G., Silva, J.C., Mendonça, A.F., Lindhe, J. (2015). Ridge alterations following grafting of fresh extraction sockets in man. A randomized clinical trial. *Clinical Oral Implants Research* **26**: 407-412.
- Artzi, Z., Tal, H., Dayan, D. (2000). Porous bovine bone mineral in healing of human extraction sockets. part 1: histomorphometric evaluations at 9 months. *Journal of periodontology* **71**: 1015-1023.
- Bakshi, M., Tarnow, D., Bittner, N. (2018). Changes in ridge dimension with pontics immediately placed at extraction sites: a pilot study. *The International Journal of Periodontics & Restorative Dentistry* **38**: 541-547.
- Baumer, D., Zuhr, O., Rebele, S., Hurzeler, M. (2017). Socket shield technique for immediate implant placement – clinical, radiographic and volumetric data after 5 years. *Clinical Oral Implants Research* **0**: 1-9.
- Becker, W., Sennerby, L., Bedrossian, E., Becker, B.E., Lucchini, J.P. (2005). Implant stability measurements for implants placed at the time of extraction: a cohort, prospective clinical trial *Journal of periodontology* **76**: 391-397.

Bornstein, M.M., Hart, C.N., Halbritter, S.A., Morton, D., Buser, D. (2009). Early loading of nonsubmerged titanium implants with a chemically modified sand-blasted and acid-etched surface: 6-month results of a prospective case series study in the posterior mandible focusing on peri-implant crestal bone changes and implant stability quotient (ISQ) values. *Clinical Implant Dentistry and Related Research* **11**: 338-347.

Chappard, D., Baslé, M.F., Legrand, E., Audran, M. (2008). Trabecular bone microarchitecture: a review. *Morphologie: Bulletin de l'Association des anatomistes* **93**: 162-170.

Dahlin, C., Linde, A., Gottlow, J., Nyman, S. (1988). Healing of bone defects by guided tissue regeneration. *Plastic and Reconstructive Surgery* **81**: 672-676.

Degidi, M., Daprile, G., Piattelli, A. (2017). Influence of stepped osteotomy on primary stability of implants inserted in low-density bone sites: an in vitro study. *The International Journal of Oral & Maxillofacial Implants* **32**: 37-41.

Ferguson, S.J., Brogini, N., Wieland, M., de Wild, M., Rupp, F., Geis-Gerstorfer, J., Cochran, D.L., Buser, D. (2006). Biomechanical evaluation of the interfacial strength of a chemically modified sandblasted and acid-etched titanium surface. *Journal of biomedical materials research* **78**: 291-297.

Fernandez de Grado, G., Keller, L., Idoux-Gillet, Y., Wagner, Q., Musset, A.M., Benkirane-Jessel, N., Bornert, F., Offner, D. (2018). Bone substitutes: a review of their characteristics, clinical use, and perspectives for large bone defects management. *Journal of Tissue Engineering* **4**: 1-18.

Fickl, S., Zuhr, O., Wachtel, H., Stappert, C.F., Stein, J.M., Hurzeler, M.B. (2008). Dimensional changes of the alveolar ridge contour after different socket preservation techniques. *Journal of clinical periodontology* **35**: 906-913.

Friedmann, A., Dard, M., Kleber, B.M., Bernimoulin, J.P., Bosshardt, D.D. (2009). Ridge augmentation and maxillary sinus grafting with a biphasic calcium phosphate: histologic and histomorphometric observations. *Clinical Oral Implants Research* **20**: 708-714.

Fu, M.W., Fu, E., Lin, F.G., Chang, W.J., Hsieh, V.D., Shen, E.C. (2017). Correlation between resonance frequency analysis and bone quality assessments at dental implant recipient sites. *The International Journal of Oral & Maxillofacial Implants* **32**: 180-187.

Herrero-Climent, M., Santos-Garcia, R., Jaramillo-Santos, R., Romero-Ruiz, M.M., Fernandez-Palacin, A., Lázaro-Calvo, P., Bullón, P., Ríos-Santos, J.V. (2013). assessment of osstell isq's reliability for implant stability measurement: a cross-sectional clinical study. *Medicina Oral, Patología Oral y Cirugía Bucal* **18**: 877-882.

Hong, J., Kurt, S., Thor, A. (2013). A hydrophilic dental implant surface exhibits thrombogenic properties in vitro. *Clinical Implant Dentistry and Related Research* **15**: 105-112.

Irie, M.S., Rabelo, G.D., Spin-Neto, R., Dechichi, P., Borges, J.S., Soares, P.B.F. (2018). Use of micro-computed tomography for bone evaluation in dentistry. *Brazilian Dental Journal* **29**: 227-238.

Jain, A., Singh, M., Ganapathy, K.P., Ramola, V., Passe, D., Jain, K. (2017). Evaluation of two socket healing procedures with and without mesenchymal stem cell: a comparative study *National Journal of Maxillofacial Surgery* **7**: 159-166.

Johansson, C.B., Albrektsson, T. (1991). A removal torque and histomorphometric study of commercially pure niobium and titanium implants in rabbit bone. *Clinical Oral Implants Research* **2**: 24-29.

Kesmas, S., Swasdison, S., Yodsanga, S., Sessirisombat, S., Jansisyanont, P. (2010). Esthetic alveolar ridge preservation with calcium phosphate and collagen membrane: preliminar report. *Oral surgery, Oral Medicine, Oral Pathology, Oral Radiology, and Endodontics* **110**: 24-36.

Khoury, F., Happe, A. (2000) The palatal subepithelial connective tissue flap method for soft tissue management to cover maxillary defects: a clinical report. *The International Journal of Oral & Maxillofacial Implants* **15**: 415-418.

Kim, H.J., Kim, Y.K., Joo, J.Y., Lee, J.Y. (2017). A resonance frequency analysis of sandblasted and acid-etched implants with diferente diameters: a prospective clinical study during the initial healing period *Journal of Periodontal & Implant Science* **47**: 106-115.

Lang, N.P., Salvi, G.E., Huynh-Ba, G., Ivanovski, S., Donos, N., Bosshardt, D.D. (2011). Early osseointegration to hydrophilic and hydrophobic implant surfaces in human. *Clinical Oral Implants Research* **22**: 349-356.

Luckerath W., Roder, L., Enkling, N. (2018). The effect of primary stabilization of the graft in a combined surgical and prosthodontics ridge preservation protocol: A prospective controlled clinical pilot study. *The International Journal of Periodontics & Restorative Dentistry* **38**: 49-58.

Mardas, N., Chadha, V., Donos, N. (2010). Alveolar ridge preservation with guided bone regeneration and a synthetic bone substitute or a bovine-derived xenograft: a randomized, controlled clinical trial. *Clinical Oral Implants Research* **21**: 688-698.

Mardas, N., D'ajuto, F., Mezzomo, L., Arzoumanidi, M., Donos, N. (2011). Radiographic alveolar bone changes following preservation with two different biomaterials. *Clinical Oral Implants Research* **22**: 416-243.

Meredith, N., Shagaldi, F., Alleyne, D., Sennerby, L., Cawley, P. (1997). The application of resonance frequency measurements to study the stability of titanium implants during healing in the rabbit tibia. *Clinical Oral Implants Research* **8**: 234-24.

McAllister, B.S., Haghghat, K. (2007). Bone augmentation techniques. *Journal of Periodontology* **78**: 377-396.

Natto, Z.S., Parashis, A., Steffensen, B., Ganguly, R., Finkelman, M.D., Jeong, Y.N. (2017). Efficacy of collagen matrix seal and collagen sponge on ridge preservation in combination with bone allograft: a randomized controlled clinical trial. *Journal of clinical periodontology* **44**: 649-659.

Park, S.H., Park, K.S., Cho, S.A. (2016). Comparison of removal torques of slactive® implant and blasted, laser-treated titanium implant in rabbit tibia bone healed with concentrated growth factor application. *The Journal of Advanced Prosthodontics* **8**: 110-115.

Qabbani, A.A., Razak, N.H.A., Kawas, S.A., Sheikh, A.H., Wahbi, S., Samsudin, A.R. (2017). The efficacy of immediate implant placement in extraction sockets for alveolar bone preservation: a clinical evaluation using three-dimensional cone beam computerized tomography and resonance frequency analysis value. *The Journal of Craniofacial Surgery* **28**: 318-335.

Rasmusson, L., Stegersjo, G., Kahnberg, K.E., Sennerby, L. (1999). Implant stability measurements using resonance frequency analysis in the grafted maxilla: a cross-sectional pilot study. *Clinical Implant Dentistry and Related Research* **2**: 70-74.

Ribeiro-Rotta, R.F., de Oliveira, R.C., Dias, D.R., Lindh, C., Leles, C.R. (2014). Bone tissue microarchitectural characteristics at dental implant sites part 2: correlation with bone classification and primary stability. *Clinical Oral Implants Research* **25**: 47-53.

Roccuzzo, M., Bunino, M., Prioglio, F., Bianchi, S.D. (2001). Early loading of sandblasted and acid-etched (SLA) implants: a prospective Split-mouth comparative study. *Clinical Oral Implants Research* **12**: 572-578.

Santamaría-Arrieta, G., Brizuela-Velasco, A., Fernández-González, F.J., Chávarru-Prado, D., Chento-Valiente, Y., Solaberrieta, E., Diéguez-Pereira, M., Veja, J.A., Yurrebaso-Asúa, J. (2016). Biomechanical evaluation of oversized drilling technique on primary implant

stability measured by insertion torque and resonance frequency analysis. *Journal of Clinical and Experimental Dentistry* **8**: 307-311.

Sjöström, M., Lundgren, S., Nilson, H., Sennerby, L. (2005). Monitoring of implants stability in grafted bone using resonance frequency analysis. a clinical study from implant placement to 6 months of loading. *International Journal of Oral and Maxillofacial Surgery* **34**: 45-51.

Vignoletti, F., Matesanz, P., Rodrigo, D., Figuero, E., Martin, C., Sanz, M. (2012) Surgical protocols for ridge preservation after tooth extraction. a systematic review. *Clinical Oral Implants Research* **23**: 22-38.

Wang, T., Li, Q., Zhang, G.F., Zhou, G., Yu, X., Zhang, J., Wang, X.M. (2016). Comparative evaluation of a biomimic collagen/hydroxyapatite/ β -tricalcium phosphate scaffold in alveolar ridge preservation with bio-oss collagen. *Frontiers of Materials Science* **10**: 122-133.

5 CONSIDERAÇÕES FINAIS

A preservação alveolar é um assunto amplamente estudado e discutido na literatura, devido a sua importância para a reabilitação de casos que, por variados motivos, não permitem a instalação imediata do implante. Esta pesquisa foi desenvolvida a partir da elaboração de uma nova técnica de preservação alveolar, uma restauração provisória de pântico ovóide, que teoricamente apresentaria vantagens para a prática clínica em relação às técnicas já estabelecidas.

A pesquisa demonstrou que o rebordo alveolar preservado pelo uso de uma restauração provisória de pântico ovóide resultou em trabéculas mais espessas, mais anisotropia, maior ISQ inicial e menos superfície óssea do que o rebordo do alvéolo comparado com o grupo que recebeu material de enxertia e que já é uma técnica bem estabelecida na literatura.

Considerados os achados desta pesquisa, juntamente com o que já se sabe sobre os diversos aspectos da neoformação óssea em pacientes nas diversas situações clínicas, sabe-se que trabéculas mais espessas podem auxiliar no processo de osseointegração. No âmbito deste estudo em pacientes saudáveis foi possível identificar osseointegração em todos os casos, no entanto, extrapolando estes dados em relação aos pacientes sistemicamente comprometidos, como por exemplo, pacientes com osteoporose ou diabetes, sugere-se que indicar a técnica PROV nestes casos poderia influenciar de forma favorável, uma vez que foi comprovado um melhor reparo ósseo a nível microtomográfico.

Por se tratar de resultados preliminares, o desfecho desta pesquisa com novos dados a cerca de preservação alveolar serão publicados com maior número de pacientes por grupos, além da abordagem de outros métodos de preservação e variação do perfil dos pacientes para obter outras análises.

Concluimos que ambas as técnicas resultam em altos valores de ITV e ISQ e que as vantagens de ser utilizar do método de restauração provisória de pântico ovóide é ter menor custo financeiro e menos repercussão biológica para o paciente, além de ser facilmente reproduzível na prática clínica do profissional.

ANEXOS

ANEXO A – CARTA DE APROVAÇÃO DO COMITÊ DE ÉTICA



UNIVERSIDADE FEDERAL DE
JUIZ DE FORA/MG



PARECER CONSUBSTANCIADO DO CEP

DADOS DO PROJETO DE PESQUISA

Título da Pesquisa: Análise clínica e tomográfica de três diferentes técnicas de preservação alveolar.

Pesquisador: Bruno Salles Sotto Maior

Área Temática:

Versão: 4

CAAE: 51514715.9.0000.5147

Instituição Proponente: FACULDADE DE ODONTOLOGIA

Patrocinador Principal: Financiamento Próprio

DADOS DO PARECER

Número do Parecer: 1.731.395

Apresentação do Projeto:

Apresentação do projeto esta clara, detalhada de forma objetiva, descreve as bases científicas que justificam o estudo, de acordo com as atribuições definidas na Resolução CNS 466/12 de 2012, item III.

Objetivo da Pesquisa:

O presente projeto tem como objetivo comparar a eficácia de 3 técnicas cirúrgicas na preservação alveolar quanto a estabilidade dimensional antes da instalação de implantes. O Objetivo da pesquisa está bem delineado, apresenta clareza e compatibilidade com a proposta, tendo adequação da metodologia aos objetivos pretendido, de acordo com as atribuições definidas na Norma Operacional CNS 001 de 2013, item 3.4.1 - 4.

Avaliação dos Riscos e Benefícios:

Os riscos envolvidos na pesquisa consistem nos desconfortos convencionais de qualquer procedimento cirúrgico de extração simples e instalação de implantes, como edema, hematoma, sangramento e dor pós-operatória. Identificação dos riscos e as possibilidades de desconfortos e benefícios esperados, estão adequadamente descritos. Tendo como benefícios a eliminação do fator causador de alterações e patologias associadas à contaminação do dente condenado (indicado à extração), como presença de cistos e infecções; proporcionará ao paciente a

Endereço: JOSE LOURENCO KELMER S/N

Bairro: SAO PEDRO

CEP: 36.036-900

UF: MG

Município: JUIZ DE FORA

Telefone: (32)2102-3788

Fax: (32)1102-3788

E-mail: cep.propesq@ufjf.edu.br



UNIVERSIDADE FEDERAL DE
JUIZ DE FORA/MG



Continuação do Parecer: 1.731.395

reabilitação funcional e estética da ausência dentária. Desta forma os benefícios do restabelecimento da saúde, funcional e psicológica dos pacientes com a reposição do dente perdido por implante, prevalecem aos

riscos e/ou desconfortos da morbidade pós-operatória de uma extração simples e instalação de implantes. Todos os pacientes participantes da pesquisa serão assistidos por um plano de monitoramento que consiste em acesso irrestrito ao atendimento na clínica de atendimento de suporte da Faculdade de Odontologia da Universidade Federal de Juiz de Fora, bem como ao contato telefônico e por email com os responsáveis pela pesquisa

durante todo o período da pesquisa, até a alta do paciente. A avaliação dos Riscos e Benefícios estão de acordo com as atribuições definidas na Resolução CNS 466/12 de 2012, itens III; III.2 e V.

Comentários e Considerações sobre a Pesquisa:

O projeto está bem estruturado, apresenta o tipo de estudo, número de participantes, critério de inclusão e exclusão, forma de recrutamento. As referências bibliográficas são atuais, sustentam os objetivos do estudo e seguem uma normatização. O cronograma mostra as diversas etapas da pesquisa, além de mostra que a coleta de dados ocorrerá após aprovação do projeto pelo CEP. O orçamento lista a relação detalhada dos custos da pesquisa que serão financiados com recursos próprios conforme consta no campo apoio financeiro. A pesquisa proposta está de acordo com as atribuições definidas na Resolução CNS 466 de 2012, itens IV.6, II.11 e XI.2; com a Norma Operacional CNS 001 de 2013. Itens: 3.4.1-6, 8, 9, 10 e 11; 3.3 - f; com o Manual Operacional para CEPS Item: VI - c; e com o Manual para submissão de pesquisa "Desenho".

Considerações sobre os Termos de apresentação obrigatória:

O protocolo de pesquisa está em configuração adequada, apresenta FOLHA DE ROSTO devidamente preenchida, com o título em português, identifica o patrocinador pela pesquisa, estando de acordo com as atribuições definidas na Norma Operacional CNS 001 de 2013 item 3.3 letra a; e 3.4.1 item 16. Apresenta o TERMO DE CONSENTIMENTO LIVRE ESCLARECIDO em linguagem clara para compreensão dos participantes, apresenta justificativa e objetivo, campo para identificação do participante, descreve de forma suficiente os procedimentos, informa que uma das vias do TCLE será entregue aos participantes, assegura a liberdade do participante recusar ou retirar o consentimento sem penalidades, garante sigilo e anonimato, explicita riscos e desconfortos esperados, ressarcimento com as despesas, indenização diante de eventuais danos decorrentes da pesquisa, contato do pesquisador e do CEP e informa que os dados da pesquisa ficarão arquivados com o pesquisador pelo período de cinco anos, de acordo com as atribuições

Endereço: JOSE LOURENCO KELMER S/N

Bairro: SAO PEDRO

CEP: 36.036-900

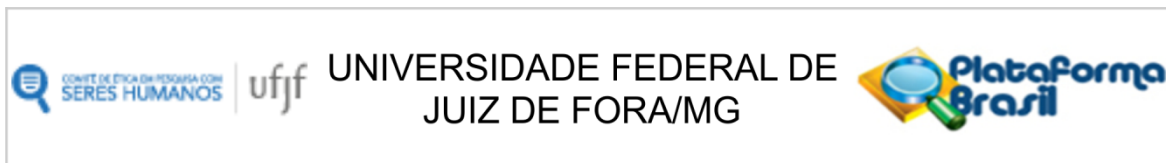
UF: MG

Município: JUIZ DE FORA

Telefone: (32)2102-3788

Fax: (32)1102-3788

E-mail: cep.propesq@ufjf.edu.br



Continuação do Parecer: 1.731.395

definidas na Resolução CNS 466 de 2012, itens: IV letra b; IV.3 letras a,b,d,e,f,g e h; IV. 5 letra d e XI.2 letra f. O Pesquisador apresenta titulação e experiência compatível com o projeto de pesquisa, estando de acordo com as atribuições definidas no Manual Operacional para CPEs. Apresenta DECLARAÇÃO de infraestrutura e de concordância com a realização da pesquisa de acordo com as atribuições definidas na Norma Operacional CNS 001 de 2013 item 3.3 letra h.

Conclusões ou Pendências e Lista de Inadequações:

Diante do exposto, o projeto está aprovado, pois está de acordo com os princípios éticos norteadores da ética em pesquisa estabelecido nas Res. 466/12, 441/11 CNS, com a Norma Operacional Nº 001/2013 e a Portaria 2.201/11 CNS. Data prevista para o término da pesquisa: Junho de 2017.

Considerações Finais a critério do CEP:

Diante do exposto, o Comitê de Ética em Pesquisa CEP/UFJF, de acordo com as atribuições definidas nas Res. 466/12, 441/11 CNS, com a Norma Operacional Nº 001/2013 e a Portaria 2.201/11 CNS, manifesta-se pela APROVAÇÃO do protocolo de pesquisa proposto. Vale lembrar ao pesquisador responsável pelo projeto, o compromisso de envio ao CEP de relatórios parciais e/ou total de sua pesquisa informando o andamento da mesma, comunicando também eventos adversos e eventuais modificações no protocolo.

Este parecer foi elaborado baseado nos documentos abaixo relacionados:

Tipo Documento	Arquivo	Postagem	Autor	Situação
Informações Básicas do Projeto	PB_INFORMAÇÕES_BÁSICAS_DO_PROJETO_633551.pdf	31/08/2016 09:51:52		Aceito
TCLE / Termos de Assentimento / Justificativa de Ausência	TCLE_biorrepositorio.doc	31/08/2016 09:51:36	Camila Furtado de Souza	Aceito
Projeto Detalhado / Brochura Investigador	Projeto_de_pesquisa.docx	04/05/2016 14:57:02	Camila Furtado de Souza	Aceito
TCLE / Termos de Assentimento / Justificativa de	TCLE.doc	04/05/2016 14:55:15	Camila Furtado de Souza	Aceito

Endereço: JOSE LOURENCO KELMER S/N
Bairro: SAO PEDRO **CEP:** 36.036-900
UF: MG **Município:** JUIZ DE FORA
Telefone: (32)2102-3788 **Fax:** (32)1102-3788 **E-mail:** cep.propesq@uff.edu.br



Continuação do Parecer: 1.731.395

Ausência	TCLE.doc	04/05/2016 14:55:15	Camila Furtado de Souza	Aceito
Declaração de Manuseio Material Biológico / Biorepositório / Biobanco	Declaracao_de_biorrepositorio.jpg	02/03/2016 19:35:42	Camila Furtado de Souza	Aceito
Declaração de Instituição e Infraestrutura	Declaracao_de_infraestrutura.docx	01/12/2015 15:09:25	Camila Furtado de Souza	Aceito
Declaração de Pesquisadores	Termo_de_sigilo.pdf	01/12/2015 15:08:04	Camila Furtado de Souza	Aceito
Folha de Rosto	Folha_de_rosto.docx	01/12/2015 15:05:40	Camila Furtado de Souza	Aceito

Situação do Parecer:

Aprovado

Necessita Apreciação da CONEP:

Não

JUIZ DE FORA, 16 de Setembro de 2016

**Assinado por:
Vânia Lúcia Silva
(Coordenador)**

Endereço: JOSE LOURENCO KELMER S/N
Bairro: SAO PEDRO **CEP:** 36.036-900
UF: MG **Município:** JUIZ DE FORA
Telefone: (32)2102-3788 **Fax:** (32)1102-3788 **E-mail:** cep.propesq@ufjf.edu.br

ANEXO B – REGISTRO DA PESQUISA NO *CLINICAL TRIALS*

ClinicalTrials.gov PRS
Protocol Registration and Results System

ClinicalTrials.gov Protocol Registration and Results System (PRS) Receipt
Release Date: May 23, 2017

ClinicalTrials.gov ID: NCT03166475

Study Identification

Unique Protocol ID: Reabilitação Oral
Brief Title: Ridge Preservation With Provisional Ovoid Pontic
Official Title: Ridge Preservation With Provisional Ovoid Pontic: a Randomized and Controlled Clinical-tomographic Trial
Secondary IDs:

Study Status

Record Verification: May 2017
Overall Status: Completed
Study Start: September 30, 2016 [Actual]
Primary Completion: January 10, 2017 [Actual]
Study Completion: March 30, 2017 [Actual]

Sponsor/Collaborators

Sponsor: Federal University of Juiz de Fora
Responsible Party: Principal Investigator
Investigator: Bruno Salles Sotto-Maior [sotto-maior]
Official Title: Clinical Professor Bruno Salles Sotto-Maior
Affiliation: Federal University of Juiz de Fora
Collaborators:

Oversight

U.S. FDA-regulated Drug: No
U.S. FDA-regulated Device: No
Unapproved/Uncleared Device: No
U.S. FDA IND/IDE: No
Human Subjects Review: Board Status: Approved
Approval Number: 1.731.395
Board Name: Comitê de Ética em Pesquisa com Seres Humanos
Board Affiliation: Universidade Federal de Juiz de Fora
Phone: +55 (32)2102-3788
Email: cep.propesq@uff.edu.br
Address:

Rua José Lourenço Kelmer, s/n - Bairro São Pedro
 CEP: 36.036-900
 Cidade: Juiz de Fora - Minas Gerais - Brasil

Data Monitoring: Yes

Plan to Share IPD: No

IPD will not be shared with other researchers, the data will be used for the same researcher on other research later.

FDA Regulated Intervention: No

Study Description

Brief Summary: A prospective randomized controlled trial of 30 patients from the Faculty of Dentistry of the UFJF was conducted. It was included patients who presented indication of extraction of premolars, canines or incisors. All the thirty patients underwent dental extraction and were randomly divided into three groups according to the study methodology. Plaster casts and Cone-Beam Computed Tomography (CBCT) exams were performed for comparative analysis between sample groups and between study times (immediate postoperative and four months later).

Detailed Description: Thirty consecutive patients who presented at the Dentistry College of Federal University of Juiz de Fora (Brazil) were selected, requiring a single-tooth extraction of premolar, canines or incisors in maxilla. All of the patients included at this study signed a free and informed consent form, agreeing to participate voluntarily in this research. The study was approved by the Research Ethical Committee of the University of Juiz de Fora under the form 1.731.395.

The patients were randomly allocated in three groups according the following treatments:

- Group 1: Closure of the socket by primary intention through a palatal pedicle subepithelial connective tissue flap by the technique of Khoury & Happe (2000) (Figure 1);
- Group 2: Filling the socket with a synthetic bone substitute of biphasic calcium phosphate (Bone Ceramic®, Straumann) and covering it with a palatal pedicle flap by the technique of Khoury & Happe (2000) (Figure 2);
- Group 3: Sealing of the socket with a provisional ovoid pontic of acrylic resin (Figure 3).

As response factors were performed evaluations of study casts and tomographic analysis for dimensional stability evaluation of the sockets at immediate postoperative and after four months of the surgical procedures.

Conditions

Conditions: Alveolar Process Atrophy

Keywords:

Study Design

Study Type: Interventional

Primary Purpose: Treatment

Study Phase: N/A

Interventional Study Model: Parallel Assignment

Number of Arms: 3

Masking: No masking

Allocation: Randomized

Enrollment: 30 [Actual]

Arms and Interventions

Arms	Assigned Interventions
<p>Experimental: Palatal pedicle flap (Group 1) On patients of this group were performed the palatal pedicle subepithelial connective tissue flap after the extraction, following the technique described by Khoury & Happe (2000), which consists of total detachment of the palatal flap followed by division of the flap to release the connective tissue, maintain a pedicle and sliding it to cover the fresh socket by primary intention. The sutures were removed seven to ten days of postoperative.</p>	<p>Procedure/Surgery: Surgical procedures All the extractions were performed under local anaesthesia, minimally traumatic as possible. After the extraction, each patient was treated according to the group of their allocations.</p>
<p>Experimental: Graft + palatal pedicle flap (Group 2) On patients of this group were performed the palatal pedicle flap like the group 1, however, the sockets were previously filled with a graft of synthetic bone substitute (Bone Ceramic®, Straumann, Switzerland) and then recovered with the connective flap and sutured by primary intention. The sutures were removed seven to ten days of postoperative.</p>	<p>Procedure/Surgery: Surgical procedures All the extractions were performed under local anaesthesia, minimally traumatic as possible. After the extraction, each patient was treated according to the group of their allocations.</p>
<p>Experimental: Provisional ovoid pontic (Group 3) On patients of this group, after the extraction of the tooth, were made a provisional ovoid pontic with acrylic resin or with the crown of the removed tooth itself, cut and sealed with composite resin. The pontics were placed to seal the entire gingival margin of the socket and penetrating 2 to 3 mm into it, stabilized laterally by the adjacent teeth with orthodontic and composite resin or acrylic resin. No sutures were made.</p>	<p>Procedure/Surgery: Surgical procedures All the extractions were performed under local anaesthesia, minimally traumatic as possible. After the extraction, each patient was treated according to the group of their allocations.</p>

Outcome Measures

Primary Outcome Measure:

- Changes of bone remodeling measured by Cone-Beam Computed Tomography exams and by plaster casts analysis, from baseline to 4 months
 Will be measured width and height buccal-lingual of the ridge for each tooth extracted by the researcher.

[Time Frame: Baseline (immediate postoperative) and 4 months after it.]

Eligibility

Minimum Age: 18 Years

Maximum Age:

Sex: All

Gender Based:

Accepts Healthy Volunteers: Yes

Criteria: Inclusion Criteria:

- Patients with indication of extraction of premolars, canines or incisors, which has two adjacent teeth, due to root fracture, extensive caries that did not allow unfavorable restorative and / or endodontic prognosis, systemically healthy.

Exclusion Criteria:

- Patients who use any drug that influences bone metabolism, patients with a history of head radiotherapy and neck, patients undergoing chemotherapy for the treatment of malignant tumors at the time of the study, patients with socket severely reabsorbed, smokers and pregnant women.

Contacts/Locations

Central Contact Person: Camila Furtado Souza, Ms.
Telephone: +55 (32) 98888-1191
Email: ca.furtado@yahoo.com.br

Central Contact Backup: Bruno Salles Sotto-Maior, Dr.
Telephone: +55 (32)98405-7663
Email: brunosottomaior@gmail.com

Study Officials:

Locations:

References

Citations: [Study Results] Ten Heggeler JM, Slot DE, Van der Weijden GA. Effect of socket preservation therapies following tooth extraction in non-molar regions in humans: a systematic review. *Clin Oral Implants Res.* 2011 Aug;22(8):779-88. doi: 10.1111/j.1600-0501.2010.02064.x. Epub 2010 Nov 22. Review. PubMed 21091540

[Study Results] Iocca O, Farcomeni A, Pardiñas Lopez S, Talib HS. Alveolar ridge preservation after tooth extraction: a Bayesian Network meta-analysis of grafting materials efficacy on prevention of bone height and width reduction. *J Clin Periodontol.* 2017 Jan;44(1):104-114. doi: 10.1111/jcpe.12633. Epub 2016 Dec 5. PubMed 27712001

[Study Results] Nevins M, Camelo M, De Paoli S, Friedland B, Schenk RK, Parma-Benfenati S, Simion M, Tinti C, Wagenberg B. A study of the fate of the buccal wall of extraction sockets of teeth with prominent roots. *Int J Periodontics Restorative Dent.* 2006 Feb;26(1):19-29. PubMed 16515093

[Study Results] Araújo MG, da Silva JC, de Mendonça AF, Lindhe J. Ridge alterations following grafting of fresh extraction sockets in man. A randomized clinical trial. *Clin Oral Implants Res.* 2015 Apr;26(4):407-12. doi: 10.1111/clr.12366. Epub 2014 Mar 12. PubMed 24621203

[Study Results] Schropp L, Wenzel A, Kostopoulos L, Karring T. Bone healing and soft tissue contour changes following single-tooth extraction: a clinical and radiographic 12-month prospective study. *Int J Periodontics Restorative Dent.* 2003 Aug;23(4):313-23. PubMed 12956475

[Study Results] Cardaropoli D, Tamagnone L, Roffredo A, Gaveglio L. Relationship between the buccal bone plate thickness and the healing of postextraction sockets with/without ridge preservation. *Int J Periodontics Restorative Dent*. 2014 Mar-Apr;34(2):211-7. doi: 10.11607/prd.1885. PubMed 24600657

[Study Results] Nart J, Barallat L, Jimenez D, Mestres J, Gómez A, Carrasco MA, Violant D, Ruiz-Magaz V. Radiographic and histological evaluation of deproteinized bovine bone mineral vs. deproteinized bovine bone mineral with 10% collagen in ridge preservation. A randomized controlled clinical trial. *Clin Oral Implants Res*. 2016 Jun 22. doi: 10.1111/clr.12889. [Epub ahead of print] PubMed 27335267

[Study Results] Jung RE, Philipp A, Annen BM, Signorelli L, Thoma DS, Hämmerle CH, Attin T, Schmidlin P. Radiographic evaluation of different techniques for ridge preservation after tooth extraction: a randomized controlled clinical trial. *J Clin Periodontol*. 2013 Jan;40(1):90-8. doi: 10.1111/jcpe.12027. Epub 2012 Nov 19. PubMed 23163915

[Study Results] Khoury F, Happe A. The palatal subepithelial connective tissue flap method for soft tissue management to cover maxillary defects: a clinical report. *Int J Oral Maxillofac Implants*. 2000 May-Jun;15(3):415-8. PubMed 10874807

[Study Results] Mardas N, Chadha V, Donos N. Alveolar ridge preservation with guided bone regeneration and a synthetic bone substitute or a bovine-derived xenograft: a randomized, controlled clinical trial. *Clin Oral Implants Res*. 2010 Jul;21(7):688-98. doi: 10.1111/j.1600-0501.2010.01918.x. PubMed 20636724

[Study Results] Ryu KH, Min S, You HK, Sin YW, Lee W, Lee J, Kiss A, Almohaimed M, Zadeh HH. Alveolar ridge dimensional changes following ridge preservation procedure using SocketKAP™ : exploratory study of serial cone-beam computed tomography and histologic analysis in canine model. *Clin Oral Implants Res*. 2016 Sep;27(9):1144-51. doi: 10.1111/clr.12711. Epub 2015 Dec 13. PubMed 26660705

[Study Results] Fickl S, Fischer K, Petersen N, Happe A, Schlee M, Schlagenhauf U, Kebschull M. Dimensional Evaluation of Different Ridge Preservation Techniques: A Randomized Clinical Study. *Int J Periodontics Restorative Dent*. 2017 May/June;37(3):403-410. doi: 10.11607/prd.2629. PubMed 28402351

Links:

Study Data/Documents:

ANEXO C – NORMAS DA REVISTA

CLINICAL ORAL IMPLANTS RESEARCH – NORMAS PUBLICAÇÃO 20/04/2017

5. MANUSCRIPT FORMAT AND STRUCTURE

5.1. Page Charge

Articles exceeding 10 published pages are subject to a charge of USD 160 per additional page. One published page amounts approximately to 5,500 characters (excluding figures and tables).

5.2. Format

Language: The language of publication is English. Authors for whom English is a second language might choose to have their manuscript professionally edited by an English speaking person before submission to make sure the English is of high quality. A list of independent suppliers of editing services can be found at http://authorservices.wiley.com/bauthor/english_language.asp. All services are paid for and arranged by the author, and use of one of these services does not guarantee acceptance or preference for publication.

Abbreviations, Symbols and Nomenclature: The symbol % is to be used for percent, h for hour, min for minute, and s for second. *In vitro*, *in vivo*, *in situ* and other Latin expressions are to be italicised. Use only standard abbreviations. All units will be metric. Use no roman numerals in the text. In decimals, a decimal point and not a comma will be used. Avoid abbreviations in the title. The full term for which an abbreviation stands should precede its first use in the text unless it is a standard unit of measurement. In cases of doubt, the spelling orthodoxy of Webster's third new international dictionary will be adhered to.

Scientific Names: Proper names of bacteria should be binomial and should be singly underlined on the typescript. The full proper name (e.g., *Streptococcus sanguis*) must be given upon first mention. The generic name may be abbreviated thereafter with the first letter of the genus (e.g., *S. sanguis*). If abbreviation of the generic name could cause confusion, the full name should be used. If the vernacular form of a genus name (e.g., streptococci) is used, the first letter of the vernacular name is not capitalised and the name is not underlined. Use of two letters of the genus (e.g., Ps. for *Peptostreptococcus*) is incorrect, even though it might avoid ambiguity. With regard to drugs, generic names should be used instead of proprietary names. If a proprietary name is used, it must be attached when the term is first used.

5.2. Structure

All manuscripts submitted to *Clinical Oral Implants Research* should include Title Page, Abstract, Main Text and Acknowledgements, Tables, Figures and Figure Legends as appropriate.

Title Page: should contain the title of the article, full name(s) of the authors (no more than 6) and institutional affiliation(s), a running title not exceeding 60 letters and spaces, and the name, telephone and fax numbers, email and complete mailing address of the author responsible for correspondence. The author must list appropriate key words for indexing purposes.

Abstract: should not to exceed 250 words. This should be structured into: objectives, material and methods, results, conclusions, and no other information.

Main Text of Original Research Article should include Introduction, Material and Methods, Results and Discussion.

Introduction: Summarise the rationale and purpose of the study, giving only strictly pertinent references. Do not review existing literature extensively. State clearly the working hypothesis.

Material and Methods: Material and methods should be presented in sufficient detail to allow confirmation of the observations. Published methods should be referenced and discussed only briefly, unless modifications have been made. Indicate the statistical methods used, if applicable. Clinical trial registration number and name of the trial register should be included in the Materials and Methods at the submission stage.

Authors who have completed the ARRIVE guidelines or STROBE checklist should include as the last sentence in the Methods section a sentence stating compliance with the appropriate guidelines/checklist.

Results: Present your results in a logical sequence in the text, tables, and illustrations. Do not repeat in the text all data in the tables and illustrations. The important observations should be emphasised.

Discussion: Summarise the findings without repeating in detail the data given in the Results section. Relate your observations to other relevant studies and point out the implications of the findings and their limitations. Cite other relevant studies.

Main Text of Short Communications: Short communications are limited to two printed pages including illustrations and references and need not follow the usual division into material and methods, etc., but should have an abstract.

Acknowledgements: Acknowledge only persons who have made substantive contributions to the study. Authors are responsible for obtaining written permission from everyone acknowledged by name because readers may infer their endorsement of the data and conclusions. Sources of financial support should be acknowledged.

5.3. References

References should quote the last name(s) of the author(s) and the year of publication (Black & Miller

1988). Three or more authors should always be referred to as, for example, (Fox et al. 1977). A list of references should be given at the end of the paper and should follow the recommendations in *Units, symbols and abbreviations: a guide for biological and medical editors and authors* (1988), p. 52, London: The Royal Society of Medicine.

a) The arrangement of the references should be alphabetical by author's surname.

b) The order of the items in each reference should be:

- (i) for journal references: name(s) of author(s), year, title of paper, title of journal, volume number, first and last page numbers.
- (ii) for book references: name(s) of author(s), year, title of book, edition, volume, chapter and/ or page number, town of publication, publisher.

c) Author's names should be arranged thus: Daniels, J.A., Kelly, R.A. & Til, T.C. Note the use of the ampersand and omission of comma before it. Author's names when repeated in the next reference are always spelled out in full.

d) The year of publication should be surrounded by parentheses: (1966).

e) The title of the paper should be included, without quotation marks.

f) The journal title should be written in full, italicised, and followed by volume number in bold type, and page numbers.

Examples:

Tonetti, M. S., Schmid, J., Hämmerle, C. H. & Lang, N. P. (1993) Intraepithelial antigen-presenting cells in the keratinized mucosa around teeth and osseointegrated implants. *Clinical Oral Implants Research* **4**: 177-186.

Poole, B., Ohkuma, S. & Warburton, M. (1978) Some aspects of the intracellular breakdown of exogenous and endogenous proteins. In: Segal, H.S. & Doyle, D.J., eds. *Protein turnover and lysosome function*, 1st edition, p. 43. New York: Academic Press.

We recommend the use of a tool such as Reference Manager for reference management and formatting. Reference Manager reference styles can be searched for here: www.refman.com/support/rmstyles.asp

5.4. Tables, Figures and Figure Legends

Tables: Tables should be numbered consecutively with Arabic numerals. Type each table on a separate sheet, with titles making them self-explanatory. Due regard should be given to the proportions of the printed page.

Figures: All figures should clarify the text and their number should be kept to a minimum. Details must be large enough to retain their clarity after reduction in size. Illustrations should preferably fill a single-column width (81 mm) after reduction, although in exceptional cases 120mm (double-column) and 168 mm (full page) widths will be accepted. Micrographs should be designed to be reproduced without reduction, and they should be dressed directly on the micrograph with a linear size scale, arrows, and other designators as needed. Each figure should have a legend

Preparation of Electronic Figures for Publication: Although low quality images are adequate for review purposes, print publication requires high quality images to prevent the final product being blurred or fuzzy. Submit EPS (lineart) or TIFF (halftone/photographs) files only. MS PowerPoint and Word Graphics are unsuitable for printed pictures. Do not use pixel-oriented programmes. Scans (TIFF only) should have a resolution of 300 dpi (halftone) or 600 to 1200 dpi (line drawings) in relation to the reproduction size (see below). EPS files should be saved with fonts embedded (and with a TIFF preview if possible). For scanned images, the scanning resolution (at final image size) should be as follows to ensure good reproduction: lineart: >600 dpi; half-tones (including gel photographs): >300 dpi; figures containing both halftone and line images: >600 dpi.

Further information can be obtained at Wiley-Blackwell's guidelines for figures: <http://authorservices.wiley.com/bauthor/illustration.asp>

Check your electronic artwork before submitting it:

<http://authorservices.wiley.com/bauthor/eachecklist.asp>

Permissions: If all or parts of previously published illustrations are used, permission must be obtained from the copyright holder concerned. It is the author's responsibility to obtain these in writing and provide copies to the Publishers.

6. AFTER ACCEPTANCE

Upon acceptance of a paper for publication, the manuscript will be forwarded to the Production Editor who is responsible for the production of the journal.

6.1 Proof Corrections

The corresponding author will receive an email alert containing a link to a web site. A working email address must therefore be provided for the corresponding author. The proof can be downloaded as a PDF (portable document format) file from this site. Acrobat Reader will be required in order to read this file. This software can be downloaded (free of charge) from the following Web site: www.adobe.com/products/acrobat/readstep2.html. This will enable the file to be opened, read

on screen, and printed out in order for any corrections to be added. Further instructions will be sent with the proof. Hard copy proofs will be posted if no e-mail address is available; in your absence, please arrange for a colleague to access your e-mail to retrieve the proofs. Proofs must be returned to the Production Editor within three days of receipt.

Excessive changes made by the author in the proofs, excluding typesetting errors, will be charged separately. Other than in exceptional circumstances, all illustrations are retained by the publisher. Please note that the author is responsible for all statements made in his work, including changes made by the copy editor.

Articles should not normally exceed 10 printed pages, including illustrations and references. Additional pages will be charged to the author(s) at the rate of USD 160 per page.

6.2 Early View (Publication Prior to Print)

Clinical Oral Implants Research is covered by Wiley-Blackwell's Early View service. Early View articles are complete full-text articles published online in advance of their publication in a printed issue. Early View articles are complete and final. They have been fully reviewed, revised and edited for publication, and the authors' final corrections have been incorporated. Because they are in final form, no changes can be made after online publication. The nature of Early View articles means that they do not yet have volume, issue or page numbers, so Early View articles cannot be cited in the traditional way. They are therefore given a Digital Object Identifier (DOI), which allows the article to be cited and tracked before it is allocated to an issue. After print publication, the DOI remains valid and can continue to be used to cite and access the article.

6.3 Author Services

Online production tracking is available for your article through Wiley-Blackwell's Author Services. Author Services enables authors to track their article - once it has been accepted - through the production process to publication online and in print. Authors can check the status of their articles online and choose to receive automated e-mails at key stages of production. The author will receive an e-mail with a unique link that enables them to register and have their article automatically added to the system. Please ensure that a complete e-mail address is provided when submitting the manuscript. Visit <http://authorservices.wiley.com/bauthor/> for more details on online production tracking and for a wealth of resources including

6.4 Guidelines for Cover Submissions

If you would like to send suggestions for artwork related to your manuscript to be considered to appear on the cover of the journal, please follow these general guidelines.

ANEXO D – CARTA DE SUBMISSÃO

02/08/2018

Email – maraisa_rc@hotmail.com

Email do Outlook

Pesquisar Email e Pessoas

Novo | Responder | Excluir | Arquivar | Lixo eletrônico | Limpar

^ Pastas

Caixa de Entrada

Lixo Eletrônico

Rascunhos

Itens Enviados

Itens Excluídos

Arquivo

Artigos

Aulas e apresentaçõ

Compras

Concursos

Conversation History

CTBMF

Documentação radic

Mestrado UFJF

Re: Fwd: Clinical Oral Implants Research - Manuscript ID COIR-Aug-18-OR-7050

N neuzapicorelli@terra.com.br

Hoje, 09:52

Você: Bruno Sotto Maior (brunosottomaior@gmail.com); dirgustavorabelo@yahoo.com.br

Cruzar os dedos!

Bj

Em Qua 01/08/18 23:08, Bruno Sotto Maior brunosottomaior@gmail.com escreveu:

AGORA SO NOS RESTA TORCER

Begin forwarded message:

From: Bernadith Millamina <bnbehalf@manuscriptcentral.com>

Subject: Clinical Oral Implants Research - Manuscript ID COIR-Aug-18-OR-7050

Date: 1 August 2018 23:07:18 GMT-3

To: brunosottomaior@gmail.com

Reply-To: CLRoffice@wiley.com

01-Aug-2018

Dear Dr. Sotto-Maior:

Your manuscript entitled "Quality of preserved alveolar ridges and influence on primary and second stability: preliminary results of a controlled and randomized clinical-microtomographic study." has been submitted online and is presently being given full consideration for publication in Clinical Oral Implants Research.

Your manuscript ID is COIR-Aug-18-OR-7050.

Please mention the above manuscript ID in all future correspondence or when calling the office for queries. If there are any changes in your street address or e-mail address, please log in to ScholarOne Manuscripts at <https://mc.manuscriptcentral.com/coir> and edit your user information as appropriate.

You can also view the status of your manuscript at any time by checking your Author Center after logging in at <https://mc.manuscriptcentral.com/coir>.

Thank you for submitting your manuscript to Clinical Oral Implants Research.

Sincerely,

Clinical Oral Implants Research Editorial Office